

# Effect of femtosecond laser-assisted lens surgery on the optic nerve head and the macula

Josefina Reñones de Abajo<sup>1,2</sup>, Beatriz Estévez Jorge<sup>1</sup>, Jesús María González Martín<sup>3</sup>, Humberto Carreras Díaz<sup>1</sup>, Juan Francisco Loro Ferrer<sup>2</sup>, Alfonso Antón López<sup>4,5,6</sup>

<sup>1</sup>Eurocanarias Oftalmológica, Las Palmas de Gran Canaria 35004, Spain

<sup>2</sup>Universidad de Las Palmas de Gran Canaria (ULPGC), Las Palmas de Gran Canaria 35001, Spain

<sup>3</sup>Department of Research, Hospital Universitario de Gran Canaria Doctor Negrín, Las Palmas de Gran Canaria 35019, Spain

<sup>4</sup>Universidad Internacional de Cataluña (UIC), Barcelona 08195, Spain

<sup>5</sup>Institut Català de Retina (ICR), Barcelona 08017, Spain

<sup>6</sup>Parc de salut Mar, Barcelona 08024, Spain

**Correspondence to:** Josefina Reñones de Abajo. Department of Cataract and Refractive Surgery and Department of Glaucoma, Clínica Eurocanarias Oftalmológica, León y Castillo 211, Las Palmas de Gran Canaria 35004, Spain. re.josefina@gmail.com

Received: 2018-10-02 Accepted: 2019-03-22

## Abstract

• **AIM:** To evaluate the effect of femtosecond laser-assisted lens surgery (FLALS; cataract surgery or refractive lens exchange) on the structure of the optic nerve head and the macula.

• **METHODS:** This prospective longitudinal study included healthy eyes undergoing FLALS. Eyes with glaucoma or any other ocular disease that could alter optical coherence tomography results were excluded. Retinal nerve fiber layer (RNFL), Bruch's membrane opening-minimum rim width (BMO-MRW) and macular thickness (MT) were measured preoperatively, 1 and 6mo after surgery using spectral-domain optical coherence tomography (SD-OCT). Changes between preoperative and postoperative values were evaluated.

• **RESULTS:** A total of 87 eyes of 46 patients were included in this study. Preoperative RNFL, BMO-MRW and MT in microns ( $\mu\text{m}$ ) were  $100.77 \pm 10.39$ ,  $330.31 \pm 49.99$  and  $276.30 \pm 33.39$ , respectively. Postoperative RNFL, BMO-MRW and MT were  $104.74 \pm 11.55$ ,  $348.32 \pm 54.05$  and  $279.83 \pm 22.65$  1mo after surgery and  $102.93 \pm 11.17$ ,  $343.11 \pm 53.4$  and  $278.90 \pm 22.19$  6mo after surgery, respectively; which equals an increase of 3.93%, 5.45% and 1.27%,

respectively, 1mo after surgery, and 2.14%, 3.87% and 0.94% 6mo after surgery. The differences between the preoperative and the postoperative RNFL and BMO-MRW values were statistically significant ( $P < 0.001$ ). Regarding MT values, there were not statistically significant differences ( $P = 0.26$ ).

• **CONCLUSION:** Our study suggests that FLALS does not have a negative impact on the structural status of the optic nerve head in healthy eyes, assessed by SD-OCT. There is a slight increase in the values of RNFL, BMO-MRW and MT 1mo and 6mo after surgery.

• **KEYWORDS:** femtosecond laser-assisted cataract surgery; refractive lens exchange; optical coherence tomography; optic nerve head; macula

**DOI:** 10.18240/ijo.2019.06.13

**Citation:** Reñones J, Estévez B, González-Martín JM, Carreras H, Loro JF, Antón A. Effect of femtosecond laser-assisted lens surgery on the optic nerve head and the macula. *Int J Ophthalmol* 2019; 12(6):961-966

## INTRODUCTION

Cataract surgery is the most commonly performed surgical procedure in the world. Recently, femtosecond laser assisted cataract surgery (FLACS) has gained popularity due to its advantages over conventional phacoemulsification such as increased accuracy and reproducibility with better refractive results, reduced endothelial cell loss, reduced effective phacoemulsification time and reduced intraoperative complication rate<sup>[1-8]</sup>. Initially FLACS was only used in healthy eyes, due to the lack of evidence regarding its effects on eyes with pathologies. However, the benefits of FLACS in certain ocular conditions have made this procedure expand its field of use. Nowadays FLACS is frequently the chosen technique for eyes with low endothelial cell count, pseudoexfoliation, narrow anterior chamber, dense cataracts, etc<sup>[1,5,9-10]</sup>. There is an increasing number of publications stating that FLACS is useful in certain conditions related to glaucoma, such as angle closure, nanophthalmos, Peters' anomaly, pseudoexfoliation or phacomorphic glaucoma<sup>[9,11-14]</sup>, despite the fact that the effect of FLACS on the optic nerve is unknown.

Femtosecond laser-assisted lens surgery (FLALS), both in case of cataract surgery and in case of refractive lens exchange, requires the application of a suction device to stabilize the laser head and focus the laser beam accurately. As a result, there is an increase in intraocular pressure (IOP), which poses potential risks, especially for patients with glaucoma. Only a few studies have evaluated the changes in the optic nerve head after a femtosecond laser procedure, as well as macular changes, and most of them have been conducted with patients undergoing laser *in situ* keratomileusis (LASIK)<sup>[15-16]</sup>. Therefore, there is a need for evidence stating whether FLALS causes changes in the optic nerve head or in the macula.

With the introduction of optical coherence tomography (OCT) both the optic nerve head and the macular structure have become easily assessable by a direct and non-invasive method. The OCT device acquires accurate measures of the retinal nerve fiber layer (RNFL), Bruch's membrane opening-minimum rim width (BMO-MRW) and macular thickness (MT), which provide information about the structural status of the optic nerve head and the macula<sup>[17-18]</sup>.

The aim of this study was to evaluate the structural changes in the optic nerve head and the macula after FLALS in healthy eyes, assessed by OCT.

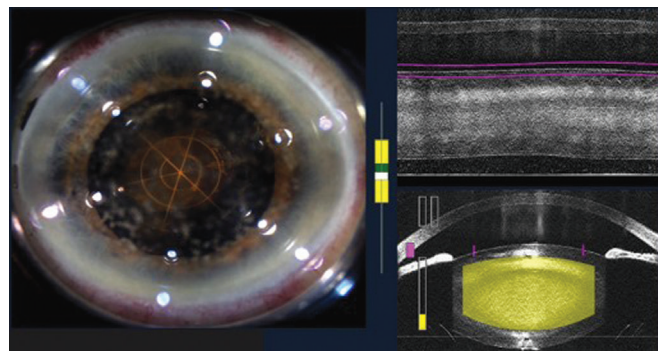
#### SUBJECTS AND METHODS

**Ethical Approval** The study was performed in compliance with the tenets of the Declaration of Helsinki. Written informed consent was obtained from all the subjects after receiving a full explanation of the procedure.

**Design and Study Group** This prospective longitudinal monocentric study included patients undergoing FLALS from September 2016 to February 2017 in Eurocanarias Oftalmológica. Since femtosecond laser-assisted refractive lens exchange requires a femtosecond laser preparation for surgery similar to that of FLACS, both types of patients were considered eligible for this study.

**Inclusion-Exclusion Criteria** Patients undergoing FLALS between September 2016 and February 2017 were included. Exclusion criteria were history of any ocular disease, particularly glaucoma, ocular hypertension or any condition that could alter OCT results (peripapillary atrophy, age related macular degeneration, difficulties in fixation, *etc.*), as well as hyperopia superior to 3 diopters, myopia superior to -3 diopters and astigmatism superior to 2 diopters.

**Examinations** All patients underwent comprehensive slit lamp examination before and 1d, 1wk, 1 and 6mo after surgery. Preoperative tests included biometry (IOL Master<sup>®</sup> 700, Carl Zeiss Meditec, Jena, Germany), Scheimpflug corneal topography (Pentacam Scheimpflug Image System, Oculus Inc. Wetzlar, Germany) and Placido-based corneal topography (Allegro Topolyzer Vario, WaveLight Technologie



**Figure 1** Femtosecond laser capsulorhexis and phacoemulsification (circular and radial pattern).

AG, Alcon Laboratories, Erlangen, Germany). Corrected and uncorrected visual acuity and applanation IOP were recorded. Prior to surgery Spectral-domain OCT (Spectralis-Glaucoma Module Premium Edition, Heidelberg Engineering, Carlsbad, CA, USA) circle and radial scans were acquired to provide RNFL and BMO-MRW measurements, respectively, as well as horizontal scans to provide MT measurements. Circle and radial scans were centered on the BMO and all scan types were aligned according to the fovea-to-BMO-center (FoBMOC) axis using the automated anatomical positioning system (APS) scan feature. The APS-based scans were repeated 1 and 6mo after surgery using the automatic “follow-up” feature in order to provide RNFL, BMO-MRW and MT measurements. Of all the measurements acquired, those used for the analysis were average RNFL, average BMO-MRW and central retinal thickness (CRT).

**Surgical Technique** The femtosecond laser platform used was LenSx (Alcon- LenSx Inc., Aliso Viejo, CA, USA). Phacoemulsification was performed using Centurion<sup>®</sup> Vision system (Alcon Laboratories Inc.). Corneal incisions were fixated at 45 and 135 degrees and capsulorhexis diameter was 5 millimetres. The nucleus fragmentation pattern chosen can be seen in Figure 1. Postoperative treatment consisted of topical application of antibiotic, steroids, nonsteroidal anti-inflammatory drugs (NSAIDs) and artificial tears.

**Statistical Analysis** Data were analysed using R Core Team 2017 (R: A language and environment for statistical computing, R Foundation for Statistical Computing, Vienna, Austria). Shapiro-Wilk normality test was used to determine if the sample was normally distributed. Mean and standard deviation (SD) of all parameters were calculated. Linear regression analysis with its respective ANOVA test and post hoc tests using the Bonferroni correction were applied. A *P*-value less than 0.05 was considered statistically significant.

#### RESULTS

The study included 87 eyes of 46 patients, of which 50.5% were right eyes and 49.5% were left eyes. There were 30 women (65.2%) and 16 men (34.8%) with a mean age of

65.7±8.16y. Most of the patients had cataracts (64.5%) and the rest of them aimed refractive lens exchange.

The mean preoperative values (±SD) of RNFL, BMO-MRW and MT in microns (µm) were 100.77±10.39, 330.31±49.99 and 276.30±33.39, respectively. There were no intraoperative or postoperative complications in the study patients. In particular, clinically significant macular edema did not appear in any of the patients in the postoperative period.

A slight increase in all parameters was observed after surgery, which can be seen in Figure 2. This increase was greater at 1mo than at 6mo post surgery. Postoperative RNFL, BMO-MRW and MT were 104.74±11.55, 348.32±54.05 and 279.83±22.65 1mo after surgery and 102.93±11.17, 343.11±53.4 and 278.90±22.19 6mo after surgery, respectively; the percentage difference is shown in Table 1. The differences between the preoperative and the postoperative RNFL and BMO-MRW values were statistically significant ( $P<0.001$ ). Regarding MT values, there were not statistically significant differences ( $P=0.26$ ). For those parameters that showed a  $P$  value smaller than 0.05 paired comparisons with Bonferroni correction were performed; Table 2 showed the groups with statistically significant differences and the confidence intervals (CI).

## DISCUSSION

The main purpose of our study was to evaluate the effect of FLALS on the optic nerve head in healthy eyes, and secondarily to assess its effect on the macula. It has been proved that FLALS induces neither more macular thickening nor higher rates of cystoid macular edema than conventional cataract surgery<sup>[19-22]</sup>. Nevertheless, there is a lack of scientific evidence regarding the effect of FLALS on the optic nerve head. Our results show a small but statistically significant increase in RNFL and BMO-MRW 1mo after surgery with a tendency to return to baseline values after 6mo. A slight increase in MT was also observed one month after surgery, with the same tendency towards reduction after 6mo. This increase in MT is similar to that published in previous studies<sup>[19-25]</sup>. The fact that RNFL and BMO-MRW values were not reduced after surgery suggests that FLALS does not have a negative impact on the structural status of the optic nerve head. Zhang *et al*<sup>[15]</sup> evaluated the RNFL before and after a different femtosecond laser-assisted procedure, femto LASIK, which causes greater IOP elevation, and they found no significant changes after surgery (mean RNFL 106.34±10.45 preoperatively, 106.01±10.35 after 1mo,  $P>0.05$ ). This is especially relevant for patients with glaucoma, in whom femtosecond laser-assisted procedures have been contraindicated so far.

There is a concern about whether the increase in IOP caused by the suction ring during the femtosecond laser procedure

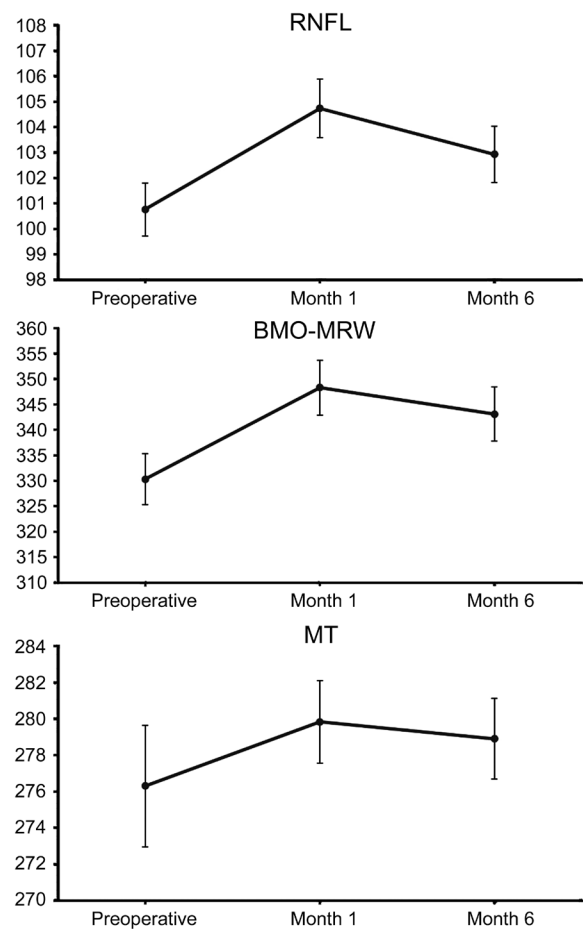


Figure 2 Changes in RNFL, BMO-MRW and MT 1mo and 6mo after surgery (mean±SD, µm).

Table 1 Percentage difference between preoperative and postoperative values of RNFL, BMO-MRW and MT %

| Percentage difference | RNFL | BMO-MRW | MT   |
|-----------------------|------|---------|------|
| 1mo postop.-preop.    | 3.93 | 5.45    | 1.27 |
| 6mo postop.-preop.    | 2.14 | 3.87    | 0.94 |

could be long and/or intense enough to damage the optic nerve head. Several authors have studied the changes in IOP induced by the different femtosecond platforms, demonstrating that those with flat and curved interfaces (LenSx and Victus) cause greater IOP increases than those with liquid interfaces (Ziemer LDV Z8 and Catalys)<sup>[26-29]</sup>. The estimated IOP increase for Victus, Ziemer LDV Z8 and Catalys is 42, 30 and <19 mm Hg, respectively<sup>[9,26-33]</sup>. Darian-Smith *et al*<sup>[34]</sup> studied 143 eyes during a FLACS procedure using a Catalys platform and found that the increase in IOP is greater in eyes with glaucoma (17.04 vs 14.01 mm Hg over baseline IOP), with no association between glaucoma severity and IOP increase during femtosecond laser pretreatment. The median vacuum time was around 150s. They concluded that it is well tolerated short term and that long-term implications are unknown. Roberts *et al*<sup>[9]</sup> made a review of literature on the LenSx platform and found an increase of 16 mm Hg during 1-2min, concluding that patients with glaucoma may not be at risk.

**Table 2 Results of paired comparisons with Bonferroni correction for the groups**

| Groups                  | Difference (µm) | SE   | 95%CI          | P      |
|-------------------------|-----------------|------|----------------|--------|
| RNFL                    |                 |      |                |        |
| 1mo postop.-preop.      | 3.97            | 0.29 | 3.29 to 4.64   | <0.001 |
| 6mo postop.-preop.      | 2.16            | 0.29 | 1.48 to 2.84   | <0.001 |
| 6mo postop.-1mo postop. | -1.80           | 0.29 | -2.48 to -1.13 | <0.001 |
| BMO-MRW                 |                 |      |                |        |
| 1mo postop.-preop.      | 18.01           | 0.92 | 15.85 to 20.17 | <0.001 |
| 6mo postop.-preop.      | 12.80           | 0.92 | 10.64 to 14.96 | <0.001 |
| 6mo postop.-1mo postop. | -5.21           | 0.92 | -7.37 to -3.05 | <0.001 |

The effect of FLALS on the measurements of RNFL, BMO-MRW and MT is the combination of the effect of 1) the femtosecond laser procedure itself, which causes the IOP increase previously discussed; 2) the effect of the phacoemulsification procedure, which also causes an intraoperative IOP increase; 3) the intraocular lens (IOL) implantation. Interestingly, the IOP levels reached during phacoemulsification have not been studied by many authors. A prospective randomized study of 80 eyes by Vasavada *et al*<sup>[35]</sup> demonstrated that the maximum IOP during phacoemulsification was 69±3.0 and 85±1.2 mm Hg in the low and high fluidic parameters groups, respectively ( $P<0.002$ ). These results are in agreement with those shown by Khng *et al*<sup>[36]</sup>, who found IOP rises of over 60 mm Hg in cadaver eyes. If the increase in IOP during surgery was long and/or intense enough to cause damage to the optic nerve head, a decrease in RNFL and BMO-MRW values would be observed after surgery. Finally, regarding the third and last part of the FLALS procedure, the IOL implanted could also affect the OCT results. Mauschitz *et al*<sup>[37]</sup> found that APS-based Spectralis scans offer reliable longitudinal data independent of media opacity changes over time, even after cataract removal, which implies that the OCT results should be equally reliable in eyes presenting cataracts, clear lens or an IOL. Nevertheless, the study by Celik *et al*<sup>[38]</sup> showed small changes in MT and RNFL values after conventional cataract surgery (MT increased from 247.9±17.6 to 249.0±17.8 and RNFL increased from 97.4±5.4 to 101.7±5.6 1mo after surgery,  $P=0.029$  and  $P<0.001$  respectively) and therefore they concluded that new baseline measurements should be obtained after surgery. These differences between the preoperative and the postoperative OCT results could be explained by a different-not necessarily better-acquisition of the images after the implantation of an IOL, and the change in refraction after surgery and the optical properties of the IOL may have an influence on this. Another parameter which could have an influence on this changes is the postoperative IOP. After glaucoma surgery, when the IOP decreases drastically, some changes in the optic disc cupping

can be seen and sometimes there is an “optic disc cupping reversal” due to the relative ocular hypotony<sup>[39]</sup>. It has been demonstrated that cataract removal causes a decrease in the IOP<sup>[40-41]</sup>, and this may have some tissue-expanding effect similar to that observed after glaucoma surgery, but to a lesser extent than in cases of optic disc cupping reversal. Despite the fact that the IOP-lowering effect of cataract surgery is not comparable to that caused by glaucoma surgery, this decrease in IOP might explain partially the increase in BMO-MRW after FLALS. Our study is the first to assess the changes not only in MT but also in RNFL and BMO-MRW after FLALS. Since RNFL and BMO-MRW are two parameters that aid in the diagnosis and monitoring of glaucoma, the fact that in healthy eyes neither of them suffers a decrease after FLALS suggests that this surgical technique may be safe not only in healthy patients but also in cases of ocular hypertension and glaucoma. However this particular topic must be addressed in future studies including ocular hypertension and glaucoma patients. This study is subject to certain limitations, such as the relatively small sample size and the fact that there was no control group. Furthermore, given the fact that the thickening observed in the three OCT parameters decreased over time, with a long-term surveillance the results shall show if the values return to baseline eventually or if the slight increase remains stable after six months, suggesting that there are new baseline values after FLALS.

In conclusion, this study showed that FLALS does not seem to cause any deterioration in the structural status of the optic nerve head in healthy eyes. Since the postoperative values of RNFL, BMO-MRW and MT are slightly superior to the preoperative values, new baseline measurements should be acquired after FLALS in order to continue the follow-up in an accurate manner. Further studies are necessary to assess if there are any long term implications and/or different results in ocular hypertension and glaucoma patients.

**ACKNOWLEDGEMENTS**

The abstract of this study was presented in the 13<sup>th</sup> Congress of the European Glaucoma Society (EGS).

**Conflicts of Interest:** Reñones J, None; Estévez B, None; González-Martín JM, None; Carreras H is consultant for Alcon; Loro JF, None; Antón A is consultant for Santen, Thea, Aerie, Alcon and Bausch+Lomb.

#### REFERENCES

- 1 Al-Mohtaseb Z, He X, Yesilirmak N, Waren D, Donaldson KE. Comparison of corneal endothelial cell loss between two femtosecond laser platforms and standard phacoemulsification. *J Refract Surg* 2017;33(10):708-712.
- 2 Chen XY, Chen KL, He JL, Yao K. Comparing the curative effects between femtosecond laser-assisted cataract surgery and conventional phacoemulsification surgery: a meta-analysis. *PLoS One* 2016;11(3):e0152088.
- 3 Popovic M, Campos-Möller X, Schlenker MB, Ahmed II. Efficacy and safety of femtosecond laser-assisted cataract surgery compared with manual cataract surgery: a meta-analysis of 14 567 eyes. *Ophthalmology* 2016;123(10):2113-2126.
- 4 Kanellopoulos AJ, Asimellis G. Standard manual capsulorhexis/ Ultrasound phacoemulsification compared to femtosecond laser-assisted capsulorhexis and lens fragmentation in clear cornea small incision cataract surgery. *Eye Vis (Lond)* 2016;3:20.
- 5 Mayer WJ, Klaproth OK, Hengerer FH, Kohnen T. Impact of crystalline lens opacification on effective phacoemulsification time in femtosecond laser-assisted cataract surgery. *Am J Ophthalmol* 2014;157(2):426-432.e1.
- 6 Abell RG, Kerr NM, Howie AR, Mustaffa Kamal MA, Allen PL, Vote BJ. Effect of femtosecond laser-assisted cataract surgery on the corneal endothelium. *J Cataract Refract Surg* 2014;40(11):1777-1783.
- 7 Rivera RP, Hoopes PC Jr, Linn SH, Hoopes PC. Comparative analysis of the performance of two different platforms for femtosecond laser-assisted cataract surgery. *Clin Ophthalmol* 2016;10:2069-2078.
- 8 Chen M, Swinney C, Chen M. Comparing the intraoperative complication rate of femtosecond laser-assisted cataract surgery to traditional phacoemulsification. *Int J Ophthalmol* 2015;8(1):201-203.
- 9 Roberts TV, Lawless M, Sutton G, Hodge C. Update and clinical utility of the LenSx femtosecond laser in cataract surgery. *Clin Ophthalmol* 2016;10:2021-2029.
- 10 Taravella MJ, Meghpara B, Frank G, Gensheimer W, Davidson R. Femtosecond laser-assisted cataract surgery in complex cases. *J Cataract Refract Surg* 2016;42(6):813-816.
- 11 Martin AI, Hughes P, Hodge C. First report of femtosecond laser cataract surgery in a nanophthalmic eye. *Clin Exp Ophthalmol* 2014;42(5):501-502.
- 12 Hou JH, Crispim J, Cortina MS, Cruz Jde L. Image-guided femtosecond laser-assisted cataract surgery in Peters anomaly type 2. *J Cataract Refract Surg* 2015;41(11):2353-2357.
- 13 Grewal DS, Basti S. Intraoperative reverse pupillary block during femtosecond laser-assisted cataract surgery in a patient with phacomorphic angle closure. *J Cataract Refract Surg* 2014;40(11):1909-1912.
- 14 Kránitz K, Takács ÁI, Gyenes A, Filkorn T, Gergely R, Kovács I, Nagy ZZ. Femtosecond laser-assisted cataract surgery in management of phacomorphic glaucoma. *J Refract Surg* 2013;29(9):645-648.
- 15 Zhang J, Zhou YH, Zheng Y, Liu Q, Zhai CB, Wang Y. Effect of suction on macular and retinal nerve fiber layer thickness during femtosecond lenticule extraction and femtosecond laser-assisted laser in situ keratomileusis. *J Cataract Refract Surg* 2014;40(12):1994-2001.
- 16 Hosny M, Zaki RM, Ahmed RA, Khalil N, Mostafa HM. Changes in retinal nerve fiber layer thickness following mechanical microkeratome-assisted versus femtosecond laser-assisted LASIK. *Clin Ophthalmol* 2013;7:1919-1922.
- 17 Sharma P, Sample PA, Zangwill LM, Schuman JS. Diagnostic tools for glaucoma detection and management. *Surv Ophthalmol* 2008;53(Suppl1):S17-S32.
- 18 Rebolleda G, Casado A, Oblanca N, Muñoz-Negrete FJ. The new Bruch's membrane opening-minimum rim width classification improves optical coherence tomography specificity in tilted discs. *Clin Ophthalmol* 2016;10:2417-2425.
- 19 Ecsedy M, Miháitz K, Kovács I, Takács A, Filkorn T, Nagy ZZ. Effect of femtosecond laser cataract surgery on the macula. *J Refract Surg* 2011;27(10):717-722.
- 20 Nagy ZZ, Ecsedy M, Kovács I, Takács Á, Tátrai E, Somfai GM, Cabrera DeBuc D. Macular morphology assessed by optical coherence tomography image segmentation after femtosecond laser-assisted and standard cataract surgery. *J Cataract Refract Surg* 2012;38(6):941-946.
- 21 Levitz L, Reich J, Roberts TV, Lawless M. Incidence of cystoid macular edema: femtosecond laser-assisted cataract surgery versus manual cataract surgery. *J Cataract Refract Surg* 2015;41(3):683-686.
- 22 Conrad-Hengerer I, Hengerer FH, Al Juburi M, Schultz T, Dick HB. Femtosecond laser-induced macular changes and anterior segment inflammation in cataract surgery. *J Refract Surg* 2014;30(4):222-226.
- 23 Asena BS, Karahan E, Kaskaloglu M. Retinal and choroidal thickness after femtosecond laser-assisted and standard phacoemulsification. *Clin Ophthalmol* 2017;11:1541-1547.
- 24 Mursch-Edlmayr AS, Bolz M, Luft N, Ring M, Kreutzer T, Ortner C, Rohleder M, Priglinger SG. Intraindividual comparison between femtosecond laser-assisted and conventional cataract surgery. *J Cataract Refract Surg* 2017;43(2):215-222.
- 25 Yu YH, Chen XY, Hua HX, Wu MH, Lai KR, Yao K. Comparative outcomes of femtosecond laser-assisted cataract surgery and manual phacoemulsification: a six-month follow-up. *Clin Exp Ophthalmol* 2016;44(6):472-480.
- 26 Schultz T, Conrad-Hengerer I, Hengerer FH, Dick HB. Intraocular pressure variation during femtosecond laser-assisted cataract surgery using a fluid-filled interface. *J Cataract Refract Surg* 2013;39(1):22-27.
- 27 Talamo JH, Gooding P, Angeley D, Culbertson WW, Schuele G, Andersen D, Marcellino G, Essock-Burns E, Batlle J, Feliz R, Friedman NJ, Palanker D. Optical patient interface in femtosecond laser-assisted cataract surgery: contact corneal applanation versus liquid immersion. *J Cataract Refract Surg* 2013;39(4):501-510.
- 28 Wu BM, Williams GP, Tan A, Mehta JS. A comparison of different operating systems for femtosecond lasers in cataract surgery. *J Ophthalmol* 2015;2015:616478.

- 29 Williams GP, Ang HP, George BL, Liu YC, Peh G, Izquierdo L, Tan DT, Mehta JS. Comparison of intra-ocular pressure changes with liquid or flat applanation interfaces in a femtosecond laser platform. *Sci Rep* 2015;5:14742.
- 30 Baig NB, Cheng GP, Lam JK, Jhanji V, Chong KK, Woo VC, Tham CC. Intraocular pressure profiles during femtosecond laser-assisted cataract surgery. *J Cataract Refract Surg* 2014;40(11):1784-1789.
- 31 Kerr NM, Abell RG, Vote BJ, Toh T. Intraocular pressure during femtosecond laser pretreatment of cataract. *J Cataract Refract Surg* 2013;39(3):339-342.
- 32 Ibarz M, Hernández-Verdejo JL, Bolívar G, Tañá P, Rodríguez-Prats JL, Teus MA. Porcine model to evaluate real-time intraocular pressure during femtosecond laser cataract surgery. *Curr Eye Res* 2016;41(4):507-512.
- 33 Sperl P, Strohmaier C, Kraker H, Motloch K, Lenzhofer M, Moussa S, Reitsamer HA. Intraocular pressure course during the femtosecond laser-assisted cataract surgery in porcine cadaver eyes. *Invest Ophthalmol Vis Sci* 2017;58(14):6457-6461.
- 34 Darian-Smith E, Howie AR, Abell RG, Kerr N, Allen PL, Vote BJ, Toh T. Intraocular pressure during femtosecond laser pretreatment: comparison of glaucomatous eyes and nonglaucomatous eyes. *J Cataract Refract Surg* 2015;41(2):272-277.
- 35 Vasavada V, Raj SM, Praveen MR, Vasavada AR, Henderson BA, Asnani PK. Real-time dynamic intraocular pressure fluctuations during microcoaxial phacoemulsification using different aspiration flow rates and their impact on early postoperative outcomes: a randomized clinical trial. *J Refract Surg* 2014;30(8):534-540.
- 36 Khng C, Packer M, Fine IH, Hoffman RS, Moreira FB. Intraocular pressure during phacoemulsification. *J Cataract Refract Surg* 2006;32(2):301-308.
- 37 Mauschitz MM, Roth F, Holz FG, Breteler MMB, Finger RP. The impact of lens opacity on SD-OCT retinal nerve fiber layer and bruch's membrane opening measurements using the anatomical positioning system (APS). *Invest Ophthalmol Vis Sci* 2017;58(5):2804-2809.
- 38 Celik E, Cakir B, Turkoglu EB, Doğan E, Alagoz G. Effect of cataract surgery on subfoveal choroidal and ganglion cell complex thicknesses measured by enhanced depth imaging optical coherence tomography. *Clin Ophthalmol* 2016;10:2171-2177.
- 39 Barrancos C, Rebolleda G, Oblanca N, Cabarga C, Muñoz-Negrete FJ. Changes in lamina cribrosa and prelaminar tissue after deep sclerectomy. *Eye (Lond)* 2014;28(1):58-65.
- 40 Yang HS, Lee J, Choi S. Ocular biometric parameters associated with intraocular pressure reduction after cataract surgery in normal eyes. *Am J Ophthalmol* 2013;156(1):89-94.e1.
- 41 Poley BJ, Lindstrom RL, Samuelson TW, Schulze R Jr. Intraocular pressure reduction after phacoemulsification with intraocular lens implantation in glaucomatous and nonglaucomatous eyes: evaluation of a causal relationship between the natural lens and open-angle glaucoma. *J Cataract Refract Surg* 2009;35(11):1946-1955.