

Journal section: Oral Surgery
 Publication Types: Review

doi:10.4317/medoral.17469
<http://dx.doi.org/doi:10.4317/medoral.17469>

Immediate implants following tooth extraction. A systematic review

Jordi Ortega-Martínez¹, Tania Pérez-Pascual², Santiago Mareque-Bueno³, Federico Hernández-Alfaro⁴,
 Eduard Ferrés-Padró⁵

¹ DDS, Master in Oral Implantology, PhD Student, Medicine, Surgery and Oral Implantology Department, Dental School, International University of Catalonia

² DDS, Master in Oral Implantology, PhD Student, Medicine, Surgery and Oral Implantology Department, Dental School, International University of Catalonia

³ DDS, Master in Oral Implantology, A. Professor, Medicine, Surgery and Oral Implantology Department, Dental School, International University of Catalonia

⁴ MD, DDS, PhD OMFS, Prof. And Director Master in Oral Implantology, Medicine, Surgery and Oral Implantology Department, Dental School, International University of Catalonia

⁵ MD, DDS, PhD OMFS, Prof. And Head of Department of Medicine, Surgery and Oral Implantology Department, Dental School, International University of Catalonia

Correspondence:

Faculty of Dentistry

Universitat Internacional de Catalunya

Josep Trueta s/n

08195 Sant Cugat del Vallès, Barcelona (Spain)

jordi.om@hotmail.com

Ortega-Martínez J, Pérez-Pascual T, Mareque-Bueno S, Hernández-Alfaro F, Ferrés-Padró E. **Immediate implants following tooth extraction. A systematic review.** Med Oral Patol Oral Cir Bucal. 2012 Mar 1;17 (2):e251-61.
<http://www.medicinaoral.com/medoralfree01/v17i2/medoralv17i2p251.pdf>

Received: 05/01/2011

Accepted: 25/03/2011

Article Number: 17469 <http://www.medicinaoral.com/>
 © Medicina Oral S. L. C.I.F. B 96689336 - pISSN 1698-4447 - eISSN: 1698-6946
 eMail: medicina@medicinaoral.com

Indexed in:

Science Citation Index Expanded
 Journal Citation Reports
 Index Medicus, MEDLINE, PubMed
 Scopus, Embase and Emcare
 Índice Médico Español

Abstract

Objectives: The aim of this article is to review the current state of immediate implants, with their pros and contras, and the clinical indications and contraindications.

Material and Methods: An exhaustive literature search has been carried out in the COCHRANE library and MEDLINE electronic databases from 2004 to November 2009. Randomized clinical trials and clinical trials focused on single implants placed in fresh extraction sockets were included and compared. A meta-analysis could not be performed due to heterogeneity of the data.

Results: Twenty studies out of 135 articles from the initial search were finally included, which summed up a total of 1139 immediate implants with at least a 12-month follow-up. Our results have been compared with other current available papers in the literature reviewed that obtained similar outcomes.

Discussion: Immediate implants have predictable results with several advantages over delayed implant placement. However, technical complications have been described regarding this technique. Also, biomaterials may be needed when the jumping distance is greater than 1mm or any bone defect is present.

Conclusions: Few studies report on success rates rather than survival rates in the literature reviewed. Short-term clinical results were described and results were comparable to those obtained with delayed implant placement. Further long-term, randomized clinical trials are needed to give scientific evidence on the benefits of immediate implants over delayed implant placement.

Key words: Immediate implants, fresh socket, dental implants, gap, jumping distance, implant stability.

Introduction

Nowadays advances in clinical techniques and biomaterials have facilitated a great expansion in the indications for dental implant treatment options.

Teeth replacement using dental implants has proven to be a successful and predictable treatment procedure; different placement and loading protocols have evolved from the first protocols in order to achieve quicker and easier surgical treatment times. Immediate placement of a dental implant in an extraction socket was initially described more than 30 years ago by Schulte and Heimke in 1976 (1).

Reductions in the number of surgical interventions, a shorter treatment time, an ideal three dimensional implant positioning, the presumptive preservation of alveolar bone at the side of the tooth extraction and soft tissue aesthetics have been claimed as the potential advantages of this treatment approach (2).

On the other hand, the morphology of the side, the presence of periapical pathology, the absence of keratinized tissue, thin tissue biotype and lack of complete soft tissue closure over the extraction socket have been reported to adversely affect in immediately placed implants (2).

The first classification described the timing of implant placement as mature, recent, delayed or immediate depending on soft tissue healing and predictability of Guided Bone Regeneration (GBR) procedures, however further classifications based on hard and soft tissue healing and treatment time approach were subsequently described, as shown in (Table 1) (3,4).

The efficacy of GBR therapy employing autogenous and non-autogenous particulate materials combined with various membranes to regenerate alveolar bone at the time of tooth extraction has also been demonstrated. Concomitant placement of regenerative materials has been shown to result in predictable, high levels of osseointegration (5).

This study will focus on the review of the current literature on immediate implant placement, in order to

understand extraction wound healing and crestal bone loss and the treatment of the jumping distance, as well as several treatment features that affect biological bone and soft tissue response compared to the delayed placement protocol.

The purpose of this review is to answer the following questions:

- Are there significant differences in crestal bone resorption between immediate and delayed implants? Where?
- Do immediate implants have a significant effect on soft tissue recession outcomes?
- Does the presence of periapical infection have an effect on the immediate implant success or survival rate?
- Does the gap treatment minimize crestal bone loss?
- Are there any significant differences in implant stability between immediate and delayed implants?

Material and Methods

A well-focused question is a very significant step to guide a high- quality and clinically purposeful systematic review. The participant, intervention, comparison, outcome (PICO) approach has been developed to state the objectives and inclusion criteria into a clear structured question (6):

Participants: Patients who needed immediate placement and restoration following extraction of a single tooth.

Intervention: Immediate implant in different clinical situations; upper jaw, lower jaw, anterior or posterior sites, implants with or without guided bone regeneration, and with or without periapical pathology.

Comparison: Immediate implants with or without guided bone regeneration, and immediate implants versus delayed implants.

Outcome: Immediate implant survival and success rates, position of the mucosal margin, mean distance from buccal bone to lingual bone, marginal bone resorption, bone loss, and implant stability.

Search Strategy & Study Selection:

The MEDLINE (PubMed) and The Cochrane Library

Table 1. Timing of implant placement.

Author / Year	Classification	Implant placement
Hämmerle et al. (2004)	Type I	In fresh extraction sockets
	Type II	After soft tissue coverage (4- 8 weeks)
	Type III	Radiographic bone fill (12-16 weeks)
	Type IV	Healed socket (>16 weeks)
Esposito et al. (2006)	Immediate	In fresh extraction sockets
	Immediate-delayed	< 8 weeks post extraction
	Delayed	> 8 weeks post extraction

Table 2a. Main inclusion criteria.

LIST OF MAIN INCLUSION CRITERIA
Randomized Clinical Trial and Prospective Controlled Trial
More than 12 months follow-up
Over 10 implants sample
Implant details described
Jumping distance treatment options
Implant stability details
Presence/ Absence of periapical infection

Table 2b. Main exclusion criteria.

LIST OF MAIN EXCLUSION CRITERIA
Unclear information about patient, implant, follow-up, study design
Study in animals
Case series/reports
Other implant protocols (delayed placement)
Being focused on patient satisfaction

databases were searched for articles published from 2004 to November 2009. The search was also restricted to articles published in English. The following search terms were used in different combinations: immediate implants, extraction socket, fresh socket, dental implants, single implant, gap, jumping distance, implant stability.

Thirty abstracts were finally selected from 135 titles in the initial search, and the full texts were obtained. Based on the evidence categories of the North of England Evidence Based Guideline Development Project (1996), only randomized clinical trials and prospective clinical trials were included in this review. Therefore, 10 articles were also excluded owing to the reasons shown in (Table 2a, b).

The articles finally selected were published in the following dental journals: International Journal of Oral and Maxillofacial Implants, Clinical Oral Implants Research, Journal of Oral and Maxillofacial Surgery, Implant Dentistry, Oral Surgery Oral Medicine Oral Pathology Oral Radiology and Endodontology, International Journal of Periodontics and Restorative Dentistry, Clinical Implant Dentistry and Related Research, and Journal of Clinical Periodontology, and were compared with similar reviews from further journals.

The review included studies of patients who needed tooth extraction due to periapical infections, unrestorable caries, trauma or periodontal disease.

When applicable, success rates found in articles were defined according to the criteria described by Albrektsson et al., which includes a reported absence of mobility, pain, peri-implant infection and suppuration, as well

as radiographic peri-implant bone loss of <1mm during the first year, followed by 0.2mm for each successive year (7). Implants were classified as surviving if the published results indicated that the implants were still in function at the time of evaluation, without fulfilling all the success criteria.

Data Extraction:

The following data were obtained using specially designed data extraction search:

Author, year of publication, journal, study design, country of origin, follow-up period, implant characteristics, presence/absence of infection, number of implants in each group, type of implants, use of regenerative procedures in the immediate placement group, crestal bone loss, soft tissue recession, implant stability, implant survival and success rates.

Results

From the initial search, 135 citations were found (Fig. 1). Based on the evidence categories of articles, 30 articles were finally selected and full texts were obtained. Ten studies were excluded after deep analysis (Table 3) (8-17). Four studies were excluded owing to an insufficient follow-up period (less than 12 months) (8, 11-13). Another one did not report any specific outcome and focused only on patient satisfaction (17). Two were clinical reports and were not included (9,15) and two more were excluded due to insufficient sample size (no more than 10 implants) (10, 14). One study was excluded because implants were placed following a delayed protocol (16).

Out of the included articles (Table 4), 8 did not include

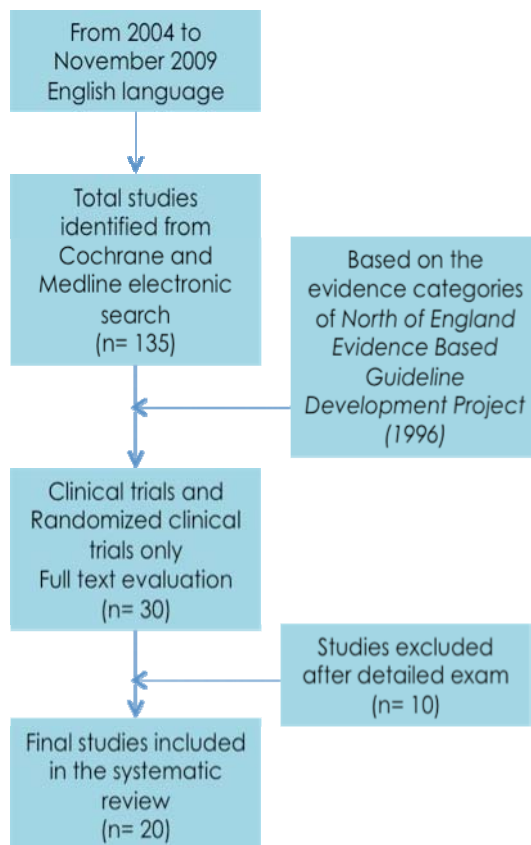


Fig. 1. Flow diagram for the search strategy

Table 3. List of excluded articles after the final selection.

Articles	Year	Reasons for exclusion
García et al	(2009)	Insufficient sample size
Raghoobar et al	(2009)	Implants were placed after bone healing
Kahngberg	(2009)	Clinical report
Covani et al	(2008)	Short follow-up prospective trial (6 months)
Canullo et al	(2007)	Insufficient sample size
Cangini et al	(2005)	Clinical report
Cornellini et al	(2004)	Short follow-up controlled clinical trial (6 months)
Covani et al	(2004)	Short follow-up prospective trial (6 months)
Botticelli et al	(2004)	Short follow-up prospective trial (4 months)
Schropp et al	(2004)	Focused on patient satisfaction

a control group (18-25). Among the included studies, all of them presented a survival rate over 90%. 1139 Immediate implants placed on 904 patients were carefully analyzed with a follow-up of 12 to 60 months.

The questions proposed in this systematic review were then answered and compared with the included articles: Are there significant differences in crestal bone resorption between immediate and delayed implants? Where?

In the prospective clinical study using platform switching, immediate implants showed reduced crestal bone loss (mean 0.08mm ± 0.53 mesial 0.09 ± 0.69 distal) (20). Nevertheless, a similar study found no difference between platform switching and platform matching (on average from 7.71 to 7.51 -0.2mm- vs. 9 to 8.57 -0.4mm-) (26).

A randomized clinical trial of 40 implants were placed

Table 4. List of Included Articles.

Author	Year	Journal	Study design	Country	Follow-up	Number of Patients	No. of Implants	Implant details	Survival / success rate	Soft tissue recession	Bone loss	Presence of infection	Treatment of gap	Implant stability
Block M. et al.	2009	JOMS	RCT	USA	18-24m	55	26 immediate 29 delayed	3i parallel wall rough surface 11.5 and 13 length	-	IP average 1mm less recession than DP	No difference in bone loss	Infection delayed placement	Allograft (mm not specified) in test group	71-79 ISQ Ostell Mentor
Calvo-Guirado J. et al.	2009	JOMI	PCT	Spain	12m	50	61	3i prevail Osseotite4/5/4 and 5/6/5 per 13 and 15mm	96.7% survival	-	Mean 0.08 ± 0.53 M 0.09 ± 0.69 D Platform switching less bone resorption	-	Covered with implant expanded platform	>60N ISQ Ostell Mentor. 71.1 ±6.2 at baseline an 75.8 ± 6.9 at 12-month
Canullo L. et al.	2009	COIR	RCT	Italy	25m	22	11 platform switching 11 platform matching	Global implant 5.5 mm	100% survival	Interprox papillae 0.88mm and 0.45 buccal recession plat match and 0.18 interprox 0.045 buc gain in plat switch on average	From 7.71 to 7.51 (-0.2mm) test from 9 to 8.57 (-0.43) control on average no difference	Acute infection excluded	Bovine bone matrix if gap over 1mm	32-45N insertion torque
Siciliano V. et al.	2009	COIR	CCT	Switzerland	12m	30	15 immediate 15 delayed	Straumann SLA	100% survival	-	-	Signs of periapical pathology excluded	Bio-Oss Bio-Gide	-
Del Fabbro M et al.	2009	JOMS	PCT	Italy	18.5	30	61	BTI acid-etched surface	Survival and success (all together) 98.4%	-	Bone loss: 0.41±0.22mm	100% periapical infection	> 1mm PRGF+ autogenous bone chips	-
Caifero C. et al	2008	COIR	PCT	Italy	12m	82	82	Straumann transmucosal 4.8mm/shoulder 6.5mm	100% survival	-	AC-BD mesial: 6.5±3.2 (baseline) 2.7±1.3(after 12m); AC-BDdistal: 4.4±2.9 (baseline) 1.6±0.8 (after12m) IS-BDmesial 5.7±3 (baseline) 2±0.8 (after12m) IS-BD distal 4.8±3.1(baseline)2.1±0.9 (after12m)	Acute periapical infection excluded	Over 1mm Bio-Oss Bio-Gide	-
Crespi R. et al.	2008	JOMI	RCT	Italy	24m	40	20 immediate 20 delayed	13mm	100% survival	-	No significant difference in bone loss	Signs of acute infection excluded	Closed with suture	-
Botticelli D. et al.	2008	COIR	PCT	Sweden	60m	18	21	Straumann SLA-cylindrical	100% survival rate	0.4mm buccal aspect//0.5mm lingual aspect.	MD aspects facing tooth bone gain 0.39±0.59 compared to implant faced implant 0.04±0.59	-	-	-

Palatella P. et al.	2008	COIR	CCT	Italy	24m	16	8 immediate 8 delayed	Straumann-tapered	-	IP-0.8±0.7 // DP-0.6±0.6mm	Bone loss:IP 0.54±0.51//DP 0.46±0.54mm	-	-	Implant placement: immediate 65±5-74±3 final restoration: immediate 72±3-73±2 ISQ Osteell Mentor
Ribeiro F. S. et al.	2008	ID	PCT	Brazil	18-39.7m	64	46 immediate 36 delayed	Conexão Sistema de Prótese Lida	Immediate success 93.5% delayed success 100%	-	-	Periapical infection excluded	Initial stability 40N insertion torque	
Lops D. et al.	2008	COIR	PCT	Italy	12m	46	46	Astra Tech Osseospeed	100% survival rate	If interprox distance was 3-4mm and contact point to bone was 3-5mm papillae present >80% and no soft tissue recession	-	-	-	
Crespi R. et al.	2007	JOMI	PCT	Italy	18m	27	150 immediate 10 delayed	Outlink titanium	100% survival	-	Distal:0.84±0.69 Mesial:0.65±0.58(max)//Distal:1.24±0.6 Mesial:1.13±0.51(jaw)	Periapical infection excluded	Implant placement: Immediate 60 Insertion torque at least 30 Ncm	
Siegenthaler D. W. et al.	2007	COIR	PCT	Switzerland	12m	29	13 periapical infection (test group) 16 without(control)	Straumann 8-1.2mm	100% survival	Loss in buccal keratinized mucosa: test - 2.2±1.2mm; control: - 1.3±1.6mm	Mesial:test 1.9±1.4control 1.8±1.1mm//distal:test 1.7±1.4control:1.6±1.1	50% with infection 50% with no infection	-	
Chen S. et al.	2007	COIR	RCT	Australia	36-48m	30	30 implants : 10-control//10-BioOss+BioGide //10-BioOss.	Transmucosa 1 Straumann	100% survival	-	-	Periapical infection excluded	-	
Lang N. G. et al.	2007	COIR	RCT	Switzerland	36m	208	208	Cylindrical/tapered	-	-	-	Periapical infection excluded	RFA was performed at this stage according to the manufacturer's instructions (Osteell, Straumann Institute)	
Lindeboom J. et al.	2006	OOOOE	RCT	Amsterdam	12m	50	25 immediate 25 delayed	Frialit immediate 5.5-6 diameter delayed 4.5-5.5 diameter	92% survival immediate 100% survival delayed	No difference between IP and DP//<1mm in 7 IP and 4 DP// <2mm in 2 IP and 0 in DP	Mesial:IP 0.49±0.11mm; DP 0.52±0.16mm//Distal: IP 0.53±0.12mm; DP 0.52±0.14mm	100% immediate and delayed implants with infection	Mean ISQ (Osteell Mentor) at 6 months IP: 64.5±3.9//DP: 64.5±4.4	

Cornelini R. et al.	2005	IJPRD	PCT	Italy	12m	22	22	ITI Straumann 4.1 per 12mm/4.1 per 10mm	100% survival	Mucosal margin position: 2.9 proximal site; 2.2 buccal site; 2.4 lingual site.	Bone resorption: 0.5mm	Signs of acute infection excluded	-	-
Villa R. et al.	2005	CIDRR	PCT	Italy	15-44m	20	194	Nobel Branemark NP, RP	100% survival	-	Marginal bone loss: 0.7mm	100% immediate implants with infection	> 1mm: autogenous bone + film of cellulose; large volume: Bio-Oss	50Nm insertion torque
Vanden Bogaerde L. et al.	2005	CIDRR	PCT	Sweden	18m	19	50 implants: 13 no defect group 33 closed defect 4 open defect	Nobel Branemark 13-15mm in maxillae; 8.5-15mm in mandible	100% survival	-	Mean marginal bone resorption: no defect: 1.1mm// closed defect: resorption 0.6mm// open defect: 2.1mm.	-	No defect: no regeneration//closed defect: autologous bone graft//open defect: bone graft+resorbable membrane.	Ostell Mentor Baseline: no defect and open defect: 60 ISQ, closed defect: 61 ISQ// 6 month: no defect and closed defect: 63 ISQ, open defect: 65 ISQ
Schropp L. et al.	2005	JCP	RCT	Denmark	24m	46	23 immediate 23 delayed	31 Osseotite	Survival rate 91% immediate; 96% delayed	-	Mesial: IP 0.5mm; DP: 0.8mm//Distal: IP 1.0mm; DP 0.6mm	-	< 2mm spontaneous healing	-

IJOMI International Journal of Oral and Maxillofacial Implants, COIR Clinical Oral Implants Research, JOMS Journal of Oral and Maxillofacial Surgery, ID Implant Dentistry, OOOOOE Oral Surgery, Oral Medicine, Oral Pathology, Oral Radiology and Endodontology, IJPRD International Journal of Periodontics and Restorative Dentistry, CIDRR Clinical Implant Dentistry and Related Research, and JCP Journal of Clinical Periodontology, RCT Randomized Clinical Trial, PCT Prospective Clinical Trial, CCT Controlled Clinical Trial.

in 40 patients in the anterior maxilla—20 immediate implants and 20 delayed implants. After a 24-month follow-up period, the control group resulted in a mean bone loss of 1.16mm and the test group of 1.02mm. Once again, there were no statistically significant differences (27).

The survival rate of early-loaded implants placed in fresh extraction sockets of teeth with endodontic and periodontal lesions in the mandible demonstrated no implants failures; a mean marginal bone loss of 0.7mm was recorded during the follow up period. No signs of infection around the implants were detected at any control visit (25).

Differences between delayed-immediate (Im) and the delayed (De) protocols for implant placement were also evaluated. A statistically significant radiographic marginal bone resorption had occurred in the Im group (mesial 0.5mm distal 1mm; mean=0.8mm) and in the De group (mesial 0.8mm distal 0.6mm; mean=0.7mm) during the follow-up period. It was demonstrated that probing pocket depths and marginal bone levels after 18 months of loading of the implant-retained crowns were not affected by the presence of peri-implant bone defects immediately after implant placement (28).

Botticelli et al. treated 18 patients with 21 immediate implants. The follow-up period was 5 years. The crestal bone loss was measured in the interproximal areas (m-d aspects facing tooth surfaces showed a higher degree of radiographic bone gain $0.39\text{mm} \pm 0.59$ compared to implant sites that faced adjacent implants $0.04\text{mm} \pm 0.59$) showing a stable bone level over time, even a gain in immediate implants (18).

According to the literature reviewed, measurements of interproximal bone levels are well recorded but few of them show differences between immediate and delayed protocols.

Do immediate implants have a significant effect on soft tissue recession outcomes?

A randomized clinical trial comparing delayed and immediate implant placement and concluded that immediate placement had an improved average gingival recession outcome of 1mm. However, crestal bone levels were not better preserved with the delayed protocol, and they concluded there were no statistically significant differences (29).

The platform switching study showed an interproximal soft tissue (papillae) of 0.88mm and a 0.45mm buccal recession in platform matching and 0.18mm and 0.045mm respectively in platform switching on average; therefore a soft tissue gain was demonstrated (26).

Measurements of soft tissue recessions in a 5-year study with an outcome of 5 buccal sites exhibited soft tissue recession; four of them were positioned in the lower jaw showing the metal margin of the restoration. The mean width of the keratinized mucosa decreased 0.3 mm

(buccal site) and 0.4mm (lingual site) during the follow up period (18).

In a 2-year follow-up study on which 16 patients were treated for single tooth replacement and randomly divided into two groups, the test group patients received immediate implants and the control group received implants in healed sites. The following parameters were evaluated: marginal bone resorption (IP $0.54\text{mm} \pm 0.51\text{mm}$ vs. DP $0.46\text{mm} \pm 0.54\text{mm}$) and the position of the mucosal margin (IP: $0.8\text{mm} \pm 0.7\text{mm}$; DP: $0.6\text{mm} \pm 0.6\text{mm}$). No statistically significant differences were found between the test and control groups, as in the study performed by Lindeboom et al. 2006 (<1mm in 7 IP and 4 DP; <2mm in 2 IP and 0 in DP) (30).

However, once again, literature of long-term follow-up studies does not show significant differences between both groups.

Does the presence of periapical infection have an effect on the immediate implant success or survival rate?

In most of the studies (19,21,26,27,29, 31-35) analyzed in this review, when a periapical infection was present the implant was not placed immediately, instead a delayed placement protocol was performed or patients were just excluded. In fact, in most texts the presence of periapical infection was an exclusion criteria.

However, the clinical outcome of implants immediately placed into fresh extraction sockets of teeth affected by chronic lesions was examined. 17 Patients with periapical infection and 17 patients without it for immediate placement were chosen in another. When infection was present, granulation tissue was removed previously and antibiotics were given (Amoxicillin 750mg 1h before the treatment and 750mg every 8hours, 5 days post-operation). From the initial 34 patients, 4 test and 1 control were excluded due to the lack of primary stability. The rest of the implants presented a survival rate of 100% after 1 year follow-up period. Periapical pathology did not show an increased rate of failures. There was a statistically significant loss of vertical bone height at the adjacent teeth and the implant site, and of buccal keratinized mucosa between baseline and 12 months in both groups (36).

Also, a randomized clinical trial conducted to evaluate clinical outcome when all implants were placed in sockets affected by chronic periapical pathology. 25 Implants were immediately placed (IP) after extraction and 25 after a 3-month healing period (DP, delayed placement). Antibiotic was only given one hour before the surgical procedure (Clyndamicine 600mg). Degranulation of the socket was immediately performed after dental extraction. Gingival recession was more prominent and clinically significant in the IP group (see (Table 4). 2 Implants from the IP group were lost, achieving a survival rate of 92% for IP implants versus 100% for DP implants (23).

Does the gap treatment minimize crestal bone loss?

Bovine bone matrix and collagen membrane is the most common grafting material when the distance between the implant and the bone wall needs to be filled in order to preserve crestal bone (19,25,26,31,33,35,36). Bio-Oss and Bio-Gide were used when the gap exceeded 1mm (19,26,33).

Nonetheless, mineralized bone allograft when needed without specifying the gap size or PRGF and autogenous bone graft to cover deshiscences were also used (22,29). Implant macrodesign as an expanded platform was taken in advantage to cover the coronal area of the gap (20). 150 Immediate implants were also placed and if the marginal defect between the implant surface and the inner wall of the extraction socket exceeded 2mm autogenous bone chips were used (32).

A prospective study evaluating healing of marginal defects in immediate transmucosal implants grafted with bovine bone matrix was performed. 30 Implants in the esthetic zone were analyzed of 30 patients that randomly received Bio-Oss (n=10), Bio-Oss and resorbable collagen membrane (n=10) or no graft as a control group (n=10). No significant differences were found regarding vertical defects, although horizontal resorption was significantly greater in the control group (31).

50 Implants were placed in fresh extraction sockets in maxillae and posterior mandibles, including defects around the implants in 19 patients. Temporary prostheses were connected immediately after surgery or within 7 days. Thirteen did not require any type of regenerative procedure (no defect), 33 were filled with autogenous bone (closed defect), and 4 were filled with autogenous bone and also had a resorbable membrane (open defect). After 18 months, none of the implants had failed. In the no defect group, the mean resorption was 1.1mm; in the closed defect group, 0.6mm and in the open defect group 2.1mm (37).

Are there any significant differences in implant stability between immediate and delayed implants?

An important clinical factor to ensure osseointegration is primary implant stability. There are several methods described to measure this parameter. The most common are: during the implant placement with the insertion torque, and resonance frequency analysis (RFA) with the Ostell Mentor device (20,23,29,30,33,37).

In Calvo-Guirado et al. study, immediately placed implants were included with an initial primary stability over 60 ISQ as measured with the Ostell Mentor. The mean ISQ values (\pm SD –standard deviation-) were 71.1 ± 6.2 at baseline and 75.8 ± 6.9 at 12-month follow-up. The differences in these results were not statistically significant (20).

Lang et al. compared primary stability of immediately placed implants of tapered versus cylindrical design using RFA. No statistically significant differences were

found. However, the authors reported that this “study had not been powered to reveal potential differences between standard cylindrical and tapered devices” (33).

Discussion

This review was designed to provide a broad perspective on the most important aspects of immediate implant placement. Due to data heterogeneity, it was impossible to perform a meta-analysis nor provide recommendations based on conclusive scientific evidence, given the lack of long-term randomized studies and relatively small sample sizes. A preferable technique could not be suggested.

Over time, clinical experience has provided the criteria for immediate implant treatment success: atraumatic tooth extraction, sterilization and minimal invasive surgical approach, as well as implant primary stability (26,34-37).

Quirynen et al. (38) focused their review on immediate versus delayed implant placement. Most papers contained only data on implant loss, but did not provide useful information on implant failure or hard and soft tissue changes. Their data match the results of the present review, in which most of the articles reported data on implant survival rates but not on implant success rates, according to the criteria described by Albrektsson et al. (7). Moreover, in The Fourth ITI Consensus Conference (November 2009), the advantages and drawbacks of the various points in time for implant placement after tooth extraction were reported. They concluded that immediate implant placement is a more difficult technique than delayed implant placement to allow initial stability and a good prosthetic position. There is also an increased risk of mucosal recession. Nonetheless, based on the aesthetic index, 80% of immediate implant sites show satisfactory outcomes. The survival rates of post-extraction implants are high and comparable to those of implants placed in healing sites, like many authors in the present review (39).

Despite many articles previously described limited marginal bone level or gain in immediate implant therapy, caution is needed because few of these studies report radiographic outcomes (4). In contrast, in our review most of the studies analyzed reported the exact millimetres immediate and delayed implants lost during the osseointegration period.

Several reviews reported that the immediate implant treatment using autogenous bone grafts or xenografts may improve the process of bone formation between the implant and the surrounding socket walls as well as survival rates (2,5). They observed that several studies have suggested that small gaps between implants and extraction sockets would fill with bone grafting procedures or without them. These data are in accordance with some results obtained in the present review

(10,19,22,23,25,26,29, 31-33, 35-37).

With regard to the gap between the socket wall and the implant, it was reported that if the jumping distance is over 2mm, grafting is recommended. Smaller distances could heal spontaneously (2,5,40). In our review, similar results on grafting the jumping distance have been contrasted. However, there is a current controversy as to which is the best grafting material (autograft, xenograft or allograft), and how big the gap should be (1-2mm).

In the Clinical Outcomes of ITI consensus, one extensive review provided strong evidence that immediate placement does not prevent vertical or horizontal resorption of the ridges in post-extraction sites. Bone augmentation following immediate placement reduces horizontal resorption on the facial bone. However, these augmentation procedures appear not to influence vertical resorption on the facial bone (39). The review also provided strong evidence that augmentation procedures are more successful with immediate implant placement than with delayed implant placement.

Few studies comparing implant stability between delayed and immediately placed implants seem to be available in the literature. From the reviewed studies, it seems that ISQ values are somewhat lower in immediately placed implants compared to implants placed in pristine bone (30). However, these differences tend to disappear overtime (23,30). ISQ values seem to increase progressively during healing over the first few months in immediate implants (20,23,30). Further controlled clinical studies should be performed in order to verify these findings.

Conclusions

There is not enough reliable evidence proving higher success of immediate implant placement over delayed placement. Post-extraction implants have survival rates similar to implants placed on healed sites. Nevertheless, some guidelines could be extracted from this review's data:

- Interproximal bone level and soft tissue recession

Crestal bone as well as soft tissue preservation could be achieved with either by immediate implant placement following tooth extraction or by a delayed protocol. No statistically significant differences were found despite the review of medium and long term follow-up studies.

- Treatment of the gap between implant and bone wall

There is no consensus whether bone augmentation with GBR at immediate implants placed into fresh extraction sites are necessary, and which is the most predictable procedure. However Bio-Oss and membranes therapy seem to show a higher position of the gingival margin.

- Presence of periapical infection

Chronic periapical infection is a risk factor but not an absolute contraindication for immediate implant place-

ment. However, debridement of the alveolus should be made. The presence of a periapical infection should be carefully weighed.

- Primary implant stability

Primary implant stability is an important factor in achieving osseointegration. Several methods have been used to quantify this parameter, such as insertion torque values and resonance frequency analysis (RFA). However, few scientific studies reveal comparative data between immediate and delayed implant placement. It seems that there are no significant differences between primary stability of immediate and delayed implants, but in both cases implant stability increases during the healing process.

Based on this review of the literature tackled, immediate implant placement following tooth extraction might be a viable alternative to delayed placement. However, it requires a careful case selection and a specific treatment protocol because it is a very sensitive technique and more difficult to execute than a conventional protocol.

References with links to Crossref - DOI

References

- Schulte W, Heimke G. The Tubinger immediate implant. *Quintessenz*. 1976;27:17 - 23.
- Chen ST, Wilson TG, Jr., Hammerle CH. Immediate or early placement of im-plants following tooth extraction: review of biologic basis, clinical procedures, and out-comes. *Int J Oral Maxillofac Implants*. 2004;19 Suppl:12-25.
- Hammerle CH, Chen ST, Wilson TG, Jr. Consensus statements and recom-mended clinical procedures regarding the placement of im-plants in extraction sockets. *Int J Oral Maxillofac Implants*. 2004;19 Suppl:26-8.
- Esposito M, Grusovin MG, Coulthard P, Worthington HV. The efficacy of vari-ous bone augmentation procedures for dental implants: a Cochrane systematic review of randomized controlled clinical trials. *Int J Oral Maxillofac Implants*. 2006;21:696-710.
- Fugazzotto PA. Treatment options following single-rooted tooth removal: a lit-erature review and proposed hierarchy of treatment selection. *J Periodontol*. 2005;76:821-31.
- Liberati A, Altman DG, Tetzlaff J, Mulrow C, Gotzsche PC, Ioannidis JP, et al. The PRISMA statement for reporting systematic reviews and meta-analyses of studies that evaluate health care interventions: explanation and elaboration. *Ann Intern Med*. 2009;151:W65-94.
- Albrektsson T, Zarb G, Worthington P, Eriksson AR. The longterm efficacy of currently used dental implants: a review and proposed criteria of success. *Int J Oral Maxillofac Implants*. 1986;1:11-25.
- Botticelli D, Berglundh T, Lindhe J. Hard-tissue alterations following immediate implant placement in extraction sites. *J Clin Periodontol*. 2004;31:820-8.
- Cangini F, Cornelini R. A comparison between enamel matrix derivative and a bioabsorbable membrane to enhance healing around transmucosal immediate post-extraction implants. *J Periodontol*. 2005;76:1785-92.
- Canullo L, Rasperini G. Preservation of peri-implant soft and hard tissues using platform switching of implants placed in immediate extraction sockets: a proof-of-concept study with 12- to 36-month follow-up. *Int J Oral Maxillofac Implants*. 2007;22:995-1000.
- Cornelini R, Cangini F, Martuscelli G, Wennstrom J. Deproteinized bovine bone and biodegradable barrier membranes to support healing following immediate placement of transmucosal implants: a short-term controlled clinical trial. *Int J Periodontics Restorative Dent*. 2004;24:555-63.

12. Covani U, Bortolaia C, Barone A, Sbordone L. Bucco-lingual crestal bone changes after immediate and delayed implant placement. *J Periodontol.* 2004;75:1605-12.
13. Covani U, Cornelini R, Barone A. Buccal bone augmentation around immediate implants with and without flap elevation: a modified approach. *Int J Oral Maxillofac Implants.* 2008;23:841-6.
14. Garcia B, Boronat A, Larrazabal C, Penarrocha M. Immediate implants after the removal of maxillary impacted canines: a clinical series of nine patients. *Int J Oral Maxillofac Implants.* 2009;24:348-52.
15. Kahnberg KE. Immediate implant placement in fresh extraction sockets: a clinical report. *Int J Oral Maxillofac Implants.* 2009;24:282-8.
16. Raghoobar GM, Slater JJ, Hartog L, Meijer HJ, Vissink A. Comparison of procedures for immediate reconstruction of large osseous defects resulting from removal of a single tooth to prepare for insertion of an endosseous implant after healing. *Int J Oral Maxillofac Surg.* 2009;38:736-43.
17. Schropp L, Isidor F, Kostopoulos L, Wenzel A. Patient experience of, and satisfaction with, delayed-immediate vs. delayed single-tooth implant placement. *Clin Oral Implants Res.* 2004;15:498-503.
18. Botticelli D, Renzi A, Lindhe J, Berglundh T. Implants in fresh extraction sockets: a prospective 5-year follow-up clinical study. *Clin Oral Implants Res.* 2008;19:1226-32.
19. Cafiero C, Annibaldi S, Gherlone E, Grassi FR, Gualini F, Magliano A, et al. Immediate transmucosal implant placement in molar extraction sites: a 12-month prospective multicenter cohort study. *Clin Oral Implants Res.* 2008;19:476-82.
20. Calvo-Guirado JL, Ortiz-Ruiz AJ, Lopez-Mari L, Delgado-Ruiz R, Mate-Sanchez J, Bravo Gonzalez LA. Immediate maxillary restoration of single-tooth implants using platform switching for crestal bone preservation: a 12-month study. *Int J Oral Maxillofac Implants.* 2009;24:275-81.
21. Cornelini R, Cangini F, Covani U, Wilson TG, Jr. Immediate restoration of implants placed into fresh extraction sockets for single-tooth replacement: a prospective clinical study. *Int J Periodontics Restorative Dent.* 2005;25:439-47.
22. Del Fabbro M, Boggian C, Taschieri S. Immediate implant placement into fresh extraction sites with chronic periapical pathologic features combined with plasma rich in growth factors: preliminary results of single-cohort study. *J Oral Maxillofac Surg.* 2009;67:2476-84.
23. Lindeboom JA, Tjiook Y, Kroon FH. Immediate placement of implants in peri-apical infected sites: a prospective randomized study in 50 patients. *Oral Surg Oral Med Oral Pathol Oral Radiol Endod.* 2006;101:705-10.
24. Lops D, Chiapasco M, Rossi A, Bressan E, Romeo E. Incidence of inter-proximal papilla between a tooth and an adjacent immediate implant placed into a fresh extraction socket: 1-year prospective study. *Clin Oral Implants Res.* 2008;19:1135-40.
25. Villa R, Rangert B. Early loading of interforaminal implants immediately in-stalled after extraction of teeth presenting endodontic and periodontal lesions. *Clin Implant Dent Relat Res.* 2005;7 Suppl 1:S28-35.
26. Canullo L, Iurlaro G, Iannello G. Double-blind randomized controlled trial study on post-extraction immediately restored implants using the switching platform concept: soft tissue response. Preliminary report. *Clin Oral Implants Res.* 2009;20:414-20.
27. Crespi R, Cappare P, Gherlone E, Romanos GE. Immediate versus delayed loading of dental implants placed in fresh extraction sockets in the maxillary esthetic zone: a clinical comparative study. *Int J Oral Maxillofac Implants.* 2008;23:753-8.
28. Schropp L, Kostopoulos L, Wenzel A, Isidor F. Clinical and radiographic performance of delayed-immediate single-tooth implant placement associated with peri-implant bone defects. A 2-year prospective, controlled, randomized follow-up report. *J Clin Periodontol.* 2005;32:480-7.
29. Block MS, Mercante DE, Lirette D, Mohamed W, Ryser M, Castellon P. Pro-spective evaluation of immediate and delayed provisional single tooth restorations. *J Oral Maxillofac Surg.* 2009;67:89-107.
30. Palattella P, Torsello F, Cordaro L. Two-year prospective clinical comparison of immediate replacement vs. immediate restoration of single tooth in the esthetic zone. *Clin Oral Implants Res.* 2008;19:1148-53.
31. Chen ST, Darby IB, Reynolds EC. A prospective clinical study of non-submerged immediate implants: clinical outcomes and esthetic results. *Clin Oral Implants Res.* 2007;18:552-62.
32. Crespi R, Cappare P, Gherlone E, Romanos GE. Immediate occlusal loading of implants placed in fresh sockets after tooth extraction. *Int J Oral Maxillofac Implants.* 2007;22:955-62.
33. Lang NP, Tonetti MS, Suvan JE, Pierre Bernard J, Botticelli D, Fourmousis I, et al. Immediate implant placement with transmucosal healing in areas of aesthetic priority. A multicentre randomized-controlled clinical trial I. Surgical outcomes. *Clin Oral Implants Res.* 2007;18:188-96.
34. Ribeiro FS, Pontes AE, Marcantonio E, Piattelli A, Neto RJ, Marcantonio E, Jr. Success rate of immediate nonfunctional loaded single-tooth implants: immediate versus delayed implantation. *Implant Dent.* 2008;17:109-17.
35. Siciliano VI, Salvi GE, Matarasso S, Cafiero C, Blasi A, Lang NP. Soft tissues healing at immediate transmucosal implants placed into molar extraction sites with buccal self-contained dehiscences. A 12-month controlled clinical trial. *Clin Oral Implants Res.* 2009;20:482-8.
36. Siegenthaler DW, Jung RE, Holderegger C, Roos M, Hammerle CH. Replacement of teeth exhibiting periapical pathology by immediate implants: a prospective, controlled clinical trial. *Clin Oral Implants Res.* 2007;18:727-37.
37. Vanden Bogaerde L, Rangert B, Wendelhag I. Immediate/early function of Branemark System TiUnite implants in fresh extraction sockets in maxillae and posterior mandibles: an 18-month prospective clinical study. *Clin Implant Dent Relat Res.* 2005;7 Suppl 1:S121-30.
38. Quirynen M, Van Assche N, Botticelli D, Berglundh T. How does the timing of implant placement to extraction affect outcome? *Int J Oral Maxillofac Implants.* 2007;22 Suppl:203-23.
39. Chen ST, Beagle J, Jensen SS, Chiapasco M, Darby I. Consensus statements and recommended clinical procedures regarding surgical techniques. *Int J Oral Maxillofac Implants.* 2009;24 Suppl:272-8.
40. Esposito M, Grusovin MG, Kwan S, Worthington HV, Coulthard P. Interventions for replacing missing teeth: bone augmentation techniques for dental implant treatment. *Cochrane Database Syst Rev.* 2008;CD003607.

Acknowledgements

The authors are very grateful for the valuable contributions to this systematic review and help from Borja Campomanes and Ariadna Casellas