

The supporting role of the teres major muscle, an additional component in glenohumeral stability? An anatomical and radiological study

M.E. Barra-López^{a,b,*}, C. López-de-Celis^{a,b,c,1}, A. Pérez-Bellmunt^{a,1}, P. Puyalto-de-Pablo^{a,1}, J.J. Sánchez-Fernández^{a,1}, M.O. Lucha-López^d

^a Faculty of Medicine and Health Sciences, International University of Catalonia, Barcelona, Spain

^b Jordi Gol Institute of Research on Primary Health Care, Barcelona, Spain

^c Baix Llobregat Centre Rehabilitation Service, DAP Costa de Ponent, Catalan Institute of Health, Barcelona, Spain

^d Faculty of Health Sciences, Physiotherapy Research Unit, University of Zaragoza, Zaragoza, Spain

ABSTRACT

Muscle coordination plays an important role in glenohumeral stability. The rotator cuff and the long head of the biceps are considered the primary dynamic stabilizers muscles. However, the fact that a subgroup of patients with a massive tear in the rotator cuff were able to keep a normal function, should make us question this traditional view.

We hypothesize that the teres major which is also a monoarticular scapulohumeral muscle, although it is not part of the conjoined tendon of the rotator cuff, can play a role in glenohumeral stability by a direct support of the humeral head generated by the particular posteroanterior location of this muscle under the humeral head and which, as far as we know, has not been written up previously. This particular effect could appear while the arm is being lifted and the humeral head could be leaning on against the teres major muscle belly underneath it.

An anatomical a radiological study was carried out to substantiate our hypothesis. Two cadaver specimens were used for the anatomical study. First body was studied through conventional dissection. The second body was analysed through sectional anatomy. Then a radiological study was carried out using magnetic resonance imaging in a healthy male volunteer.

Both anatomically and radiologically, the anteroinferior surface of the humeral head was showed firmly resting against the muscle belly of the teres major, to the point of misshaping it from 110 degrees of arm elevation with external rotation. The specific contribution of this effect to the glenohumeral stability needs to be confirmed by further studies and can help us to prevent the high incidence of glenohumeral dislocations.

Introduction

The glenohumeral joint has the largest range of motion of any joint of the human body, but to the detriment of its stability. Owing to its limited means of passive stability [1], it needs coordinated activation of the stabilizing musculature so as to maintain the articular congruence throughout its broad range of movement [2,3]. The rotator cuff muscles, the deltoid muscle and the long head of the biceps muscle, have traditionally been regarded as the primary dynamic stabilizers of the glenohumeral joint [4,5]. The activation of the rotator cuff generates a stabilizing mechanism known as concavity-compression mechanism [6], creating a fulcrum around which other muscles can add strength to the movement. The cuff provides stability both in the coronal plane while the arm is being raised, and in the sagittal plane through the balance of the anterior and posterior muscles of the cuff [7,8]. Nevertheless, the fact that a subgroup of patients with a massive tear in the rotator cuff were able to keep their limb functioning normally, should

make us question whether this traditional view is accurate [9].

Teres Major muscle although it is not part of the conjoined tendon of the rotator cuff and inserts further away from the humeral head [10], it is also a monoarticular scapulohumeral muscle [11] that is inserted in the same plane that the subscapularis muscle [12] and has an activity direction only 9° different from that of the subscapularis [13].

We hypothesize that teres major muscle can play a role in glenohumeral stability by a mechanism caused by its particular posteroanterior location under the humeral head (Fig. 1).

While the arm is being lifted the humeral head could be leaning on the muscle belly underneath it, providing a support opposing to the anteroinferior displacement of the humeral head (Fig. 2) which, as far as we know, has not been written up previously.

Methods

The research was carried out in two stages: the first through an

* Corresponding author at: Carrer Marià Sanjuan Cuchí, num 21, 5° 1ª, 08840 Viladecans, Barcelona, Spain.

E-mail address: mbarra@uic.es (M.E. Barra-López).

¹ Faculty of Medicine and Health Sciences, International University of Catalonia, Carrer de Josep Trueta, s/n, 08195 Sant Cugat del Vallès Barcelona, Spain.

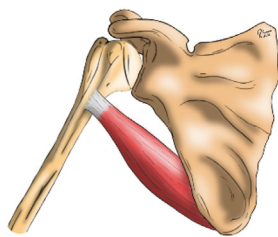


Fig. 1. Drawing of the teres major muscle. Front view.

anatomical study performed on two cadaver specimens and the second through a radiological study using magnetic resonance imaging.

In the anatomical study two specimens were made available from the Servei de Donació de Cos of the Universitat Internacional de Catalunya, (*The body donation service of the International University of Catalonia*). Both were male with no sign of surgical intervention in the shoulder area. In one case the anatomical study was done through conventional dissection, by planes, following the indications of anatomical treatises [14]. The second body was analysed through sectional anatomy every four centimetres in a plane perpendicular to the humeral diaphysis, for which the body was cryopreserved in a position of 110° flexion, 45° abduction and external rotation of the shoulder.

A magnetic resonance (MR) with Turbo Spin-echo (TSE) T2-weighted images (WI) was performed on the right shoulder of a 40 years old, male volunteer, with no pathological records or previous injury, in 180° elevation (swimmer's view) which corresponds to the position of the anatomical sample in Fig. 5.

Results

In the cadaveric models the firm support of the humeral head on the teres major muscle belly could be seen when elevation occurred. In Fig. 3 we can see the 110° abduction position with internal glenohumeral rotation, showing the contact of the humeral head with the muscle belly.

In Fig. 4 the same abduction position is seen but with external rotation, showing that the pressure the humeral head exercises are substantially increased to the point it causes a muscle deformation cross-wise to the direction of the fibres.

From 110° of abduction to the maximum elevation (Fig. 5), the firm contact of the humeral head in the muscular belly of the teres major was observed constantly, and also the deformation of the latter cross-wise to the direction of its muscular fibres as a result of the pressure exercised by the humeral head. In maximum elevation position the muscle belly of the teres major totally covers the lower part of the humeral head.

Fig. 6, shows a cut in the proximal third of the limb of the cryopreserved specimen, where the teres major muscle and the latissimus dorsi tendon could be seen surrounding the humeral diaphysis.

The magnetic resonance images are shown in Fig. 7. In a sequence from posterior to anterior (coronal section parallel to the glenohumeral joint), you can see that in the more posterior images the teres minor muscle is above the triceps brachii (Fig. 7a and b). From the insertion of the triceps brachii (Fig. 7c) the teres major muscle and the latissimus dorsi are behind the triceps (Fig. 7d) and at the end of the sequence the teres major muscle is deformed by the pressure the humeral head is putting on it (Fig. 7e and f).

Discussion

This study shows that during the elevation of the limb the antero-inferior surface of the humeral head rested against the muscle belly of the teres major muscle, to the point of misshaping it. This direct support of the humeral head may contribute to maintaining glenohumeral joint

stability and as far as we know has not been written about previously.

Evidence about a possible contribution of the teres major muscle to glenohumeral stability is so sparse. Inman et al., in their classic work in which they established the role of the rotator cuff muscles as opponents of the deltoid during elevation, arrived at the odd conclusion that (sic) "The teres major occupies a special position in the scapulohumeral musculature. The muscle never exhibits any activity during motion, but plays a peculiar role in that it only comes into action when it is necessary to maintain a static position" [4]. De Baets et al., in their review of scapular biomechanics only refer to the teres major muscle to say that (sic) "Apart from the prolonged rotator cuff activity, m. teres major is also believed to be more active in instable shoulders in order to pull down the humeral head. Such contraction of m. teres major further increases scapular lateral rotation during elevation. This in turn contributes to pain avoidance or reduction" [15]. Lugo et al., in their review of shoulder biomechanics comment that (sic) "The dynamic stabilizing structures include the rotator cuff muscles and the other muscular structures surrounding the shoulder joint", but do not mention the teres major muscle in their work [16].

The muscular contribution to glenohumeral stability is not only the consequence of its contractile activity. Ward et al., studied the architecture of the rotator cuff muscles and the length of the sarcomeres in different positions and found out that they showed not only serious active tensions, particularly in the medium range of movement, but also lead to passive tensions in the final range of movement. The supraspinatus and infraspinatus have relatively high passive tension in the anatomical position and are the stabilizers in rest position, while the subscapularis shows high passive tension in abduction and external rotation (apprehension position), an antagonist movement for it [17]. Although the teres major muscle has not been studied in this context, we cannot rule out that the passive tension generated by the deformation it undergoes from the 110° abduction position with external rotation, may be a contributing factor to joint stabilization for preventing antero-inferior displacement of the humeral head. Furthermore, owing to its posteroanterior location, its line of action could oppose it more effectively to the anterior displacement of the humeral head.

The review by Sangwan et al., has shown that the rotator cuff muscles do not present all the necessary characteristics to be considered stabilizing muscles. Although the rotator cuff muscles restrict the movement of the humeral head, they increase joint strength and present a smaller moment arm than other motor muscles, there are limited evidence that the rotator cuff muscles become activated before the global musculature and they do not show a clear pattern of co-contraction as a group but rather seem to go into action in a specific way according to the movement. Therefore these authors conclude that the dynamic stabilizing role of the rotator cuff muscles seems to restrict itself to restrain the movement of the humeral head in a specific way according to each muscle [18].

Hawkes et al., have evaluated the coordination of the muscle activity, in asymptomatic subjects, in a functional gesture consisting of repeatedly lifting (phase 1) and lowering (phase 2) a one kilogram weight from a shelf located at the same level as the anterosuperior iliac spine of the subject to another shelf located 25 cm higher, and the results show that the teres major muscle becomes activated before the rotator cuff muscles and maintains its peak activity for longer. Also, the latissimus dorsi and the teres major are more active during phase 1 (elevation) than during phase 2 (lowering). The difference between both phases was more important and statistically significant in the case of the teres major muscle, which contradicts the traditional view of synergy between the deltoid and the rotator cuff when lifting the limb [9]. More recently Hawkes et al., have studied muscle coordination during dynamic arm elevation and found a particularly high correlation between the deltoid and a functional adducting group comprising the latissimus dorsi and teres major during early shoulder elevation. These authors suggest a stabilizing role for the rotator cuff, latissimus dorsi and teres major muscles during the initial phase of shoulder elevation

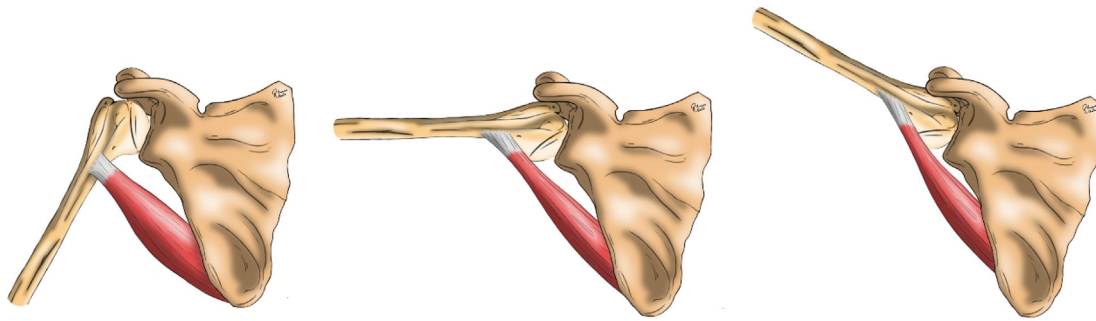


Fig. 2. Sketched representation of the supporting role of the humeral head provided by the teres major muscle during the elevation of the arm.

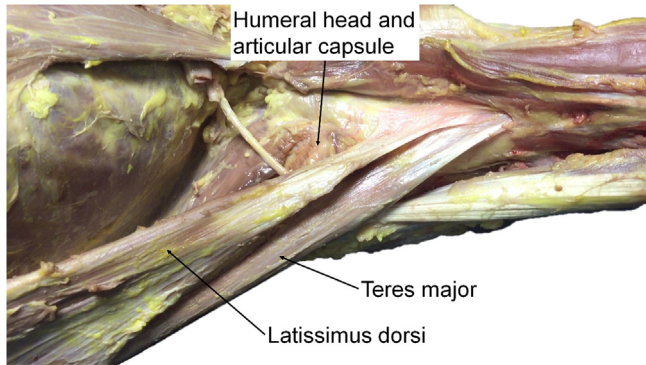


Fig. 3. 110° abduction position and internal glenohumeral rotation causing the humeral head to make contact with the muscle belly of the teres major muscle.

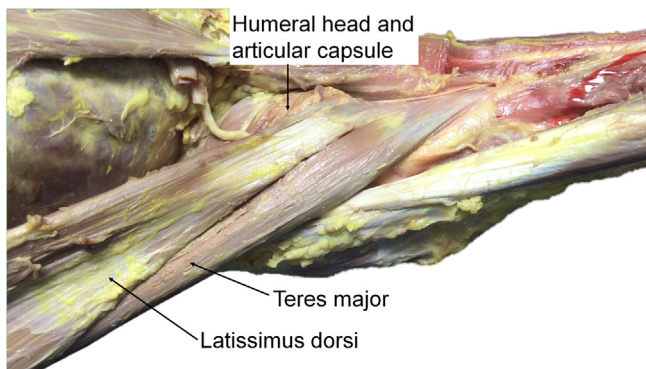


Fig. 4. 110° abduction position and external glenohumeral rotation in which the pressure the humeral head exercises on the muscle belly of the teres major makes it expand crosswise to the direction of its fibres.

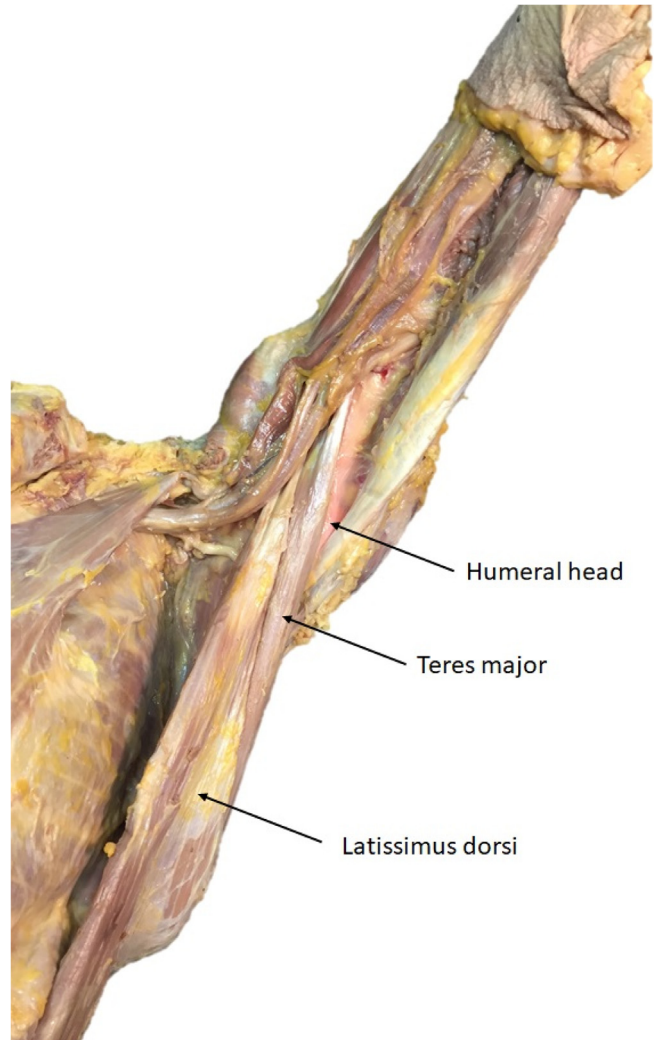


Fig. 5. Position of maximum elevation.

[19].

Nor can we rule out an active stabilizing effect in the mid-range of elevation when the teres major muscle, which in 87% of cases it is innervated by the same motor nerve as the lower part of the subscapularis muscle (lower subscapular nerve) [20] and its line of action is only 9° different from that of the subscapularis [13], may increase the concavity compression mechanism generated by the rotator cuff muscles.

As shoulder elevation continues to progress the force vector exerted by muscles like the deltoid or the pectoralis major comes to pass below the axis of the glenoid generating inferior shear forces which can lead to instability [2,21]. Nevertheless luxatio erecta is the least frequent of glenohumeral dislocations [22]. In the elevated position, as showed in this anatomical and radiological study, the teres major muscle belly surrounds the humeral head and can prevent its inferior displacement.

Our paper is a descriptive study with some limitations such as the limited number of anatomical and radiological studies and the absence of electrophysiological data to support our hypothesis.

This study describes the mechanism by which the humeral head is supported by the teres major muscle belly to the point of misshaping it during arm elevation. This mechanism that could be named “hammock effect” could generate a passive tension to support the humeral head and could increase the concavity compression mechanism. We believe that further studies to confirm these possible effects are needed for a better understanding of the muscular contribution to glenohumeral joint stability to help us to prevent the high incidence of glenohumeral dislocations.

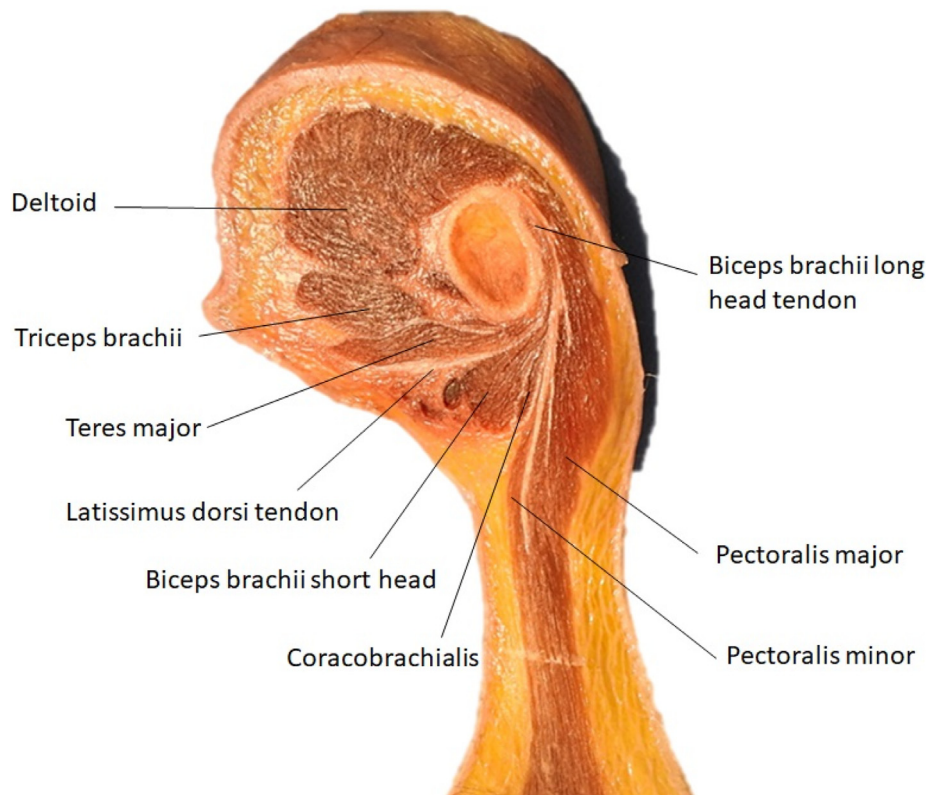


Fig. 6. Anatomical cut of the arm close to the glenohumeral joint.

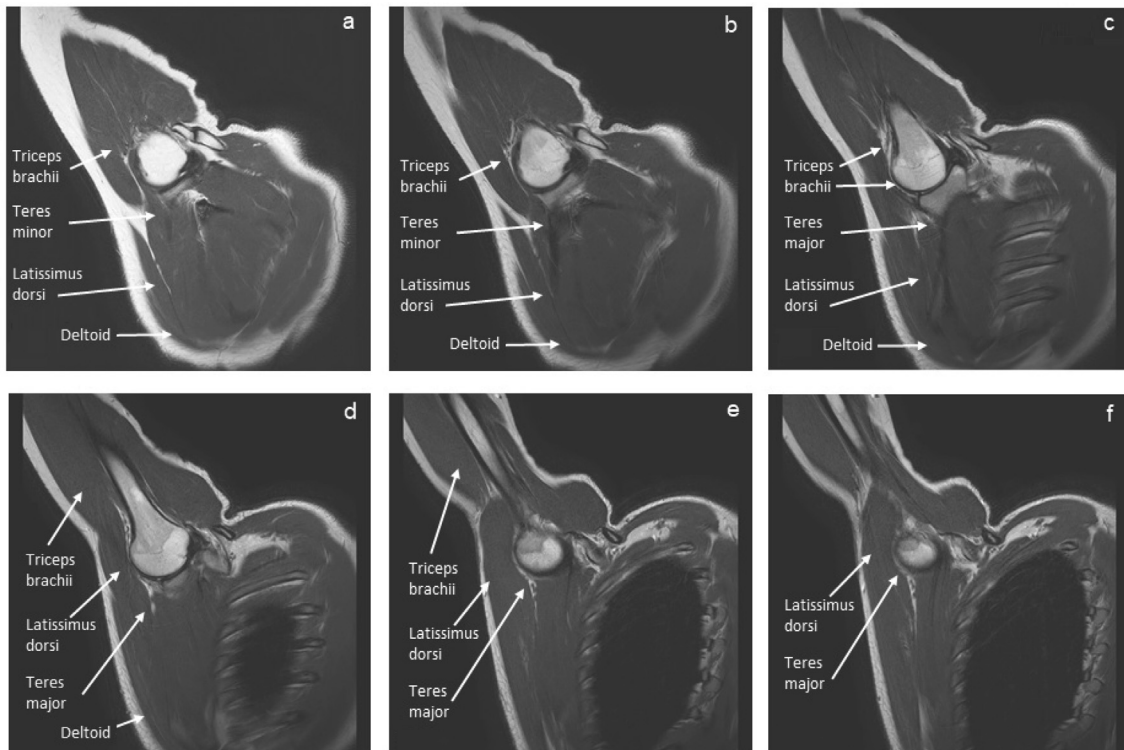


Fig. 7. Coronal MR T2 TSE WI right glenohumeral joint in posteroanterior direction.

Conflict of interest statement

All authors declare that no conflicts of interest exist. This research did not receive any specific grant from funding agencies in the public, commercial, or non-for-profit sectors.

Acknowledgements

The Authors wish to thank all corpse donors for their generosity, which allows anatomical sciences to advance.

The Authors wish to thank to all the staff at Servei de Donació de Cos of the Universitat Internacional de Catalunya for their help and professionalism.

Appendix A. Supplementary data

Supplementary data to this article can be found online at <https://doi.org/10.1016/j.mehy.2020.109728>.

References

- [1] Massimini DF, Boyer PJ, Papannagari R, Gill TJ, Warner JP, Li G. In-vivo glenohumeral translation and ligament elongation during abduction and abduction with internal and external rotation. *J Orthop Surg Res* 2012;7:29.
- [2] Wilk KE, Arrigo CA, Andrews JR. Current concepts: the stabilizing structures of the glenohumeral joint. *J Orthop Sports Phys Ther* 1997;25:364–79.
- [3] Yanagawa T, Goodwin CJ, Shelburne KB, Giphart JE, Torry MR, Pandy MG. Contributions of the individual muscles of the shoulder to glenohumeral joint stability during abduction. *J Biomech Eng* 2008;130:021024.
- [4] Inman VT, Saunders JB, Abbott LC. Observations on the function of the shoulder joint. *J Bone Joint Surg Am* 1944;26:1–30.
- [5] Drake RL, Wayne Vogl A, Mitchell AWM. *Gray's anatomy for students*. 3rd ed. Elsevier; 2015.
- [6] Lippitt S, Matsen F. Mechanisms of glenohumeral joint stability. *Clin Orthop Relat Res* 1993;291:20–8.
- [7] Kronberg M, Németh G, Broström LA. Muscle activity and coordination in the normal shoulder. An electromyographic study. *Clin Orthop Relat Res* 1990;257:76–85.
- [8] Graichen H, Hinterwimmer S, von Eisenhart-Rothe R, Vogl T, Englmeier KH, Eckstein F. Effect of abducting and adducting muscle activity on glenohumeral translation, scapular kinematics and subacromial space width in vivo. *J Biomech* 2005;38:755–60.
- [9] Hawkes DH, Alizadehkhayati O, Fisher AC, Kemp GJ, Roebuck MM, Frostick SP. Normal shoulder muscular activation and co-ordination during a shoulder elevation task based on activities of daily living: an electromyographic study. *J Orthop Res* 2012;30:53–60.
- [10] Beck PA, Hoffer MM. Latissimus dorsi and teres major tendons: separate or conjoint tendons? *J Pediatr Orthop* 1989;9:308–9.
- [11] Rouvière H, Delmas A. *Anatomía humana descriptiva, topográfica y funcional*. Tomo 3 Miembros. 9ª ed. 86-99 (Masson, 1987).
- [12] Dancker M, Lambert S, Brenner E. Teres major muscle – insertion footprint. *J Anat* 2017;230:631–8.
- [13] Lafosse T, Le Hanneur M, Lee J, Elhassan B. Bipolar pedicled teres major transfer for irreparable subscapularis tendon tears: an anatomic feasibility study. *J Shoulder Elbow Surg* 2018;27:931–9.
- [14] Testut L, Billet H, Jacob O. *Atlas de dissection por regiones*. Salvat; 1958.
- [15] De Baets L, Jaspers E, Desloovere K, Van Deun S. A systematic review of 3D scapular kinematics and muscle activity during elevation in stroke subjects and controls. *J Electromyogr Kinesiol* 2013;23:3–13.
- [16] Lugo R, Kung P, Ma CB. Shoulder biomechanics. *Eur J Radiol* 2008;68:16–24.
- [17] Ward SR, Hentzen ER, Smallwood LH, et al. Rotator cuff muscle architecture: implications for glenohumeral stability. *Clin Orthop Relat Res* 2006;448:157–63.
- [18] Sangwan S, Green RA, Taylor NF. Stabilizing characteristics of rotator cuff muscles: a systematic review. *Disabil Rehabil* 2015;37:1033–43.
- [19] Hawkes DH, Khaiyat OA, Howard AJ, Kemp GJ, Frostick SP. Patterns of muscle coordination during dynamic glenohumeral joint elevation: an EMG study. *PLoS One* 2019;14:e0211800.
- [20] Dancker M, Lambert S, Brenner E. The neurovascular anatomy of the teres major muscle. *J Shoulder Elbow Surg* 2015;24:e57–67.
- [21] Labriola JE, Lee TQ, Debski RE, McMahon PJ. Stability and instability of the glenohumeral joint: the role of shoulder muscles. *J Shoulder Elbow Surg* 2005;4:32S–8S.
- [22] Faizan M, Jilani LZ, Abbas M, et al. Inferior glenohumeral joint dislocation with greater tuberosity avulsion. *Chin J Traumatol* 2015;18:181–3.