

Journal section: *Implantology*
 Publication Types: *Review*

doi:10.4317/medoral.23248
<https://dx.doi.org/doi:10.4317/medoral.23248>

Short implants (<8mm) versus longer implants (≥8mm) with lateral sinus floor augmentation in posterior atrophic maxilla: A meta-analysis of RCT's in humans

Naroa Lozano-Carrascal ¹, Albert Anglada-Bosqued ², Oscar Salomó-Coll ¹, Federico Hernández-Alfaro ³, Hom-Lay Wang ⁴, Jordi Gargallo-Albiol ⁵

¹ Assistant Professor. International Master's Degree in Oral Surgery. Oral and Maxillo-facial Surgery Department. International University of Catalonia. Barcelona, Spain

² International Master's Degree in Oral Surgery Student. International University of Catalonia. Oral and Maxillo-facial Surgery Department. Barcelona, Spain

³ Professor and Chairman of the Department of Oral and Maxillofacial Surgery. International University of Catalonia, Barcelona, Spain

⁴ Professor and Director of Graduate Periodontics, Department of Periodontics and Oral Medicine. University of Michigan, School of Dentistry. Michigan. USA

⁵ Associate Professor and Director of International Master in Oral Surgery. Oral and Maxillo-facial Surgery Department. International University of Catalonia, Barcelona, Spain

Correspondence:

Surgery Department. International University of Catalonia
 Josep trueta s/n, Sant Cugat del Valles, Barcelona, Spain
oscarsalomo@uic.es

Received: 02/06/2019

Accepted: 20/01/2020

Lozano-Carrascal N, Anglada-Bosqued A, Salomó-Coll O, Hernández-Alfaro F, Wang HL, Gargallo-Albiol J. Short implants (<8mm) versus longer implants (≥8mm) with lateral sinus floor augmentation in posterior atrophic maxilla: A meta-analysis of RCT's in humans. *Med Oral Patol Oral Cir Bucal*. 2020 Mar 1;25 (2):e168-79.

Article Number: 23248 <http://www.medicinaoral.com/>
 © Medicina Oral S. L. C.I.F. B 96689336 - pISSN 1698-4447 - eISSN: 1698-6946
 eMail: medicina@medicinaoral.com
Indexed in:
 Science Citation Index Expanded
 Journal Citation Reports
 Index Medicus, MEDLINE, PubMed
 Scopus, Embase and Emcare
 Índice Médico Español

Abstract

Background: One of the greatest challenges that dentists face today is to rehabilitate severe atrophied alveolar ridges in partially and completely edentulous patients with implants. Despite the high survival rate of implants placed next to sinus elevation, this technique presents complications that can be avoided by placing short implants, an option that also presents high survival rates.

For this reason, the aim of this study is to compare the survival rate, marginal bone loss and complications associated with short implants (<8 mm) versus longer implants (≥8mm) placed with lateral sinus floor elevation in posterior atrophic maxillae.

Material and Methods: A literature search was conducted by two independent reviewers in the PubMed/Medline (National Library of Medicine, Washington, DC) electronic database for articles published from January 2007 to July 2018. Seven qualified articles were selected for the meta-analysis.

Results: The test for overall effect did not find statistical significance in the survival rates, overall complications, intra-operative complications, post-operative complications and prosthetic complications. However, the test showed statistically significant differences in biological complications in favor of standard implants, and marginal bone loss between control and test groups in favor of short implants (<8mm) was found.

Conclusions: Within the limitations of the present study, prosthetic rehabilitations with short implants (<8mm) in posterior maxilla is a reliable treatment option as an alternative to lateral wall sinus floor augmentation.

Key words: *Short implant, lateral sinus floor augmentation, Randomized controlled trial, Survival rate, Complications, Marginal bone loss.*

Introduction

One of the greatest challenges that dentists face today is to rehabilitate severe atrophied alveolar ridges in partially and completely edentulous patients with implants. Following tooth loss, jaws undergo vertical collapse due to increased osteoclast activity, which takes place in response to the absence of functional load transmission to the alveolar bone. Bone resorption is aggravated by the physiological process of sinus pneumatization especially in the maxillary posterior area (1). Therefore, bone quantity and quality is often insufficient for the ideal three-dimensional (3D) implant positioning. Several bone augmentation techniques have been proposed to overcome these problems. Among these, Sinus floor elevation is considered to be the most reliable surgical technique for increasing bone height in the posterior maxilla (2). Two sinus floor elevation techniques have been described by Wang *et al.* [2008] (3): lateral approach (LSFE), when the residual bone volume is less than ≤ 5 mm, or crestal (CSFE) approach when residual bone height is more than 6 mm. Both techniques have reported Research reports high survival rates, 100% after 5-year follow-up (4) and 97% after a 10-year follow-up (5) and success rates 98% after a 3-year follow-up (6).

Due to the high percentage of anatomical variations among patients (7) and the sensitivity of the technique, these procedures are not exempt from complications: Schneiderian membrane perforation, sinusitis, nasal bleeding, hematomas, post-operative pain, dehiscence, graft failure, or migration of the implant into the sinus cavity are common complications associated with sinus floor elevation surgery (8,9). For this reason, several alternatives have been proposed to avoid sinus lifting, such as tilted implants or short implants (10).

Recently, implants as short as 8 mm have been considered as standard implants in several published articles (11). Short implants are slowly being accepted by patients and clinicians because they are associated with a less invasive procedure, leading to a smaller scale intervention, shorter intra-operative time, less morbidity, and lower treatment cost (12). Traditionally, short implants have been related to lower survival rates and unpredictable outcomes. But more recently, technical and manufacturing developments have improved implant surfaces and connections and nowadays short implants have a failure rate of under 4% for ≤ 8 mm implants, a failure rate similar to longer implants (13).

The aim of the present study was to compare the survival rate, marginal bone loss and complications associated with short implants (<8 mm) versus longer implants (≥ 8 mm) placed with lateral sinus floor elevation in posterior atrophic maxillae.

Material and Methods

- Study Registration

This systematic review and meta-analysis has been registered in the Prospero Database (International prospective register of systematic reviews - <https://www.crd.york.ac.uk/prospero/>) under the title: "Short implants (<8mm) versus longer implants (≥ 8 mm) with lateral sinus floor augmentation in posterior atrophic maxilla: A meta-analysis of RCT's in humans" (ID:92413).

- Focused Question

Following Preferred Reporting Items for Systematic Reviews and Meta-Analyses (PRISMA) guidelines (14), a specific answerable question was formulated according to PICO(S) recommendations (Participants, Interventions, Control, Outcomes, Study):

(P) Participants: Patients who received at least one dental implant in the posterior area of the upper maxilla.

(I) Type of intervention: at least one short dental implant placement (<8mm) in the posterior area of the upper maxilla without lateral sinus floor elevation procedure.

(C) Control intervention: at least one long dental implant (≥ 8 mm) placed simultaneously or deferred with sinus membrane elevation via lateral sinus floor elevation procedure.

(O) Outcome measures: implant survival rate, intra- and post-operative surgical complications, biological and prosthetic post-operative complications, marginal bone loss (MBL).

(S) Study type: randomized controlled clinical trials (RCTs).

- Search Strategy

A literature search was conducted by two independent reviewers (LN and AA) in the MEDLINE, EMBASE, Cochrane Central Register of Controlled Trials, and Cochrane Oral Health Group Trials Register databases. The research included references up to July 2018, using different combinations and Boolean Operators (AND, OR, NOT) with the following search terms/key words: "short implants", "longer implant", "standard implant", "bone augmentation", "sinus lift", "randomized control trial", "atrophic maxilla", "posterior maxilla".

Following the electronic search, a further manual search

was performed in the websites of the leading scientific journals on dentistry and implant dentistry.

Crossed-references were screened to identify other potentially relevant articles.

- Eligibility criteria

Studies were deemed eligible if they met the following criteria: 1) Human subjects with posterior maxilla atrophy; 2) Randomized Clinical Trials (RCT); 3) the presence of a study group (receiving one or more short implant (<8 mm) and a control group (receiving long implants ≥ 8 mm) simultaneously or deferred with lateral sinus floor elevation); 4) studies with a minimum follow-up period of >12 months after prosthesis placement; 5) results providing data on survival rates, complications, and marginal bone loss; 6) articles published in English. Exclusion criteria comprised of: 1) animal studies; 2) human studies with less than 15 subjects with posterior maxilla atrophy; 3) studies with a follow-up of <12 months after prosthetic loading; 4) prospective cohort studies, case reports, case series, retrospective studies, systematic reviews; and 5) articles that failed to provide sufficient information.

- Data extraction

The following information was extracted from the publications included for analysis: 1) author and year of publication; 2) duration of follow-up; 3) patient and implant sample; 4) systemic, periodontal, and smoking status; 5) time of loading; 6) implant location; 7) setting and funding; 8) preoperative preparation; 9) treatment control group; 10) treatment study group; 11) residual bone height; 12) post-surgical instructions; 13) augmentation technique; 14) survival rate; 15) intra/post-operative and biological/prosthetic complications; 16) marginal bone loss (MBL); and 17) study conclusions as reported by the authors.

Two reviewers (LN and AA) carried out the selection process, screening the articles' titles and abstracts. The full texts of all studies of possible relevance were then obtained, and eligibility assessment and data extraction were performed independently in an un-blinded standardized manner by the two authors; any disagreement between the reviewers was resolved through discussion. When the reviewers did not agree, a third reviewer (SO) analyzed the text to decide whether the article should be included or excluded.

- Quality Assessment

The reviewers A.A and N.L assessed the quality of each study independently. Disagreements on validity assessment were resolved by consensus and discussion; when consensus could not be reached, a third reviewer was consulted (JG). The methodological quality of the RCT's were assessed using the Cochrane Risk of Bias Tool for Randomized Controlled Trials (Table 1).

- Statistical Analysis

Statistical analysis was performed using R Project soft-

ware© (The R Foundation, Bell Laboratories, formerly AT&T, now Lucent Technologies by John Chambers and Colleagues). The Chi² test was used to evaluate heterogeneity across the studies; subgroup analysis was performed when heterogeneity was significant (*p-value* <0.05) and the I² statistic expressed the percentage of heterogeneity, with 25% corresponding to low heterogeneity, 50% to moderate, and 75% to high. A test of overall effects was used to evaluate significance between the groups; a *p-value* of less than 0.05 was considered statistically significant. A forest plot was drawn to represent estimates of relative effect, expressed as risk ratio (RR) with a 95% confidence interval (CI).

Results

- Study selection

Search results based on the PRISMA guidelines are depicted in Fig. 1. The initial search identified 482 titles, 476 PubMed Embase Database and 6 additional records identified through hand-searching. After elimination by screening all titles and abstracts, twenty-one studies were left for full-text assessment. After full-text screening, 14 articles were excluded due to failed to meet the inclusion criteria (Table 1) (15-29), leaving a total of 8 RTCs (30-37) for inclusion in the meta-analysis (Table 2).

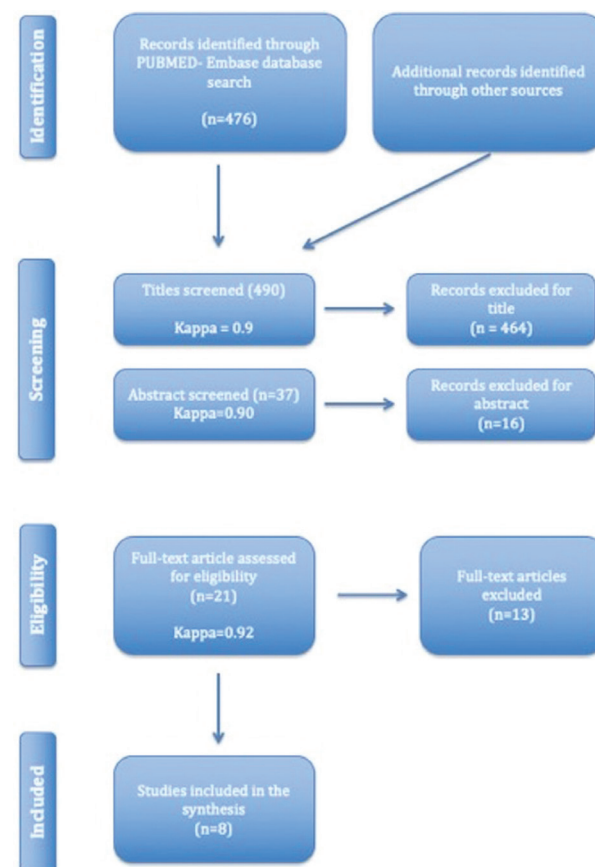


Fig. 1: PRISMA flowchart of the screening process in different databases.

Table 1: Excluded Studies.

Reason for exclusion	Number	Studies
Short implants ≥ 8 mm	4	Canizzaro <i>et al.</i> 2009; (15) Canizzaro <i>et al.</i> 2013; (16) Esposito <i>et al.</i> 2015; (17) Taschieri; (18)
Mean follow-up < 1 year	4	Felice <i>et al.</i> 2009; (19) Esposito <i>et al.</i> 2012; (20) Esposito <i>et al.</i> 2015; (21) Esposito <i>et al.</i> 2016 (22)
More recent follow-up papers available	2	Pistilli <i>et al.</i> 2013; (23) Thoma <i>et al.</i> 2015 (24)
Data for maxillary implants could not be separated from mandibular implants	2	Esposito <i>et al.</i> 2011; (25) Felice <i>et al.</i> 2016 (26)
OSFE instead of LSFE	2	Felice <i>et al.</i> 2015(27); Zhang <i>et al.</i> 2017(28); Yu <i>et al.</i> 2017(29);
Total	14	

Note. OSFE: Osteotome sinus floor elevation. LSFE: Lateral sinus floor elevation.

Table 2: General overview of the studies included for analysis.

Study	Study design, follow-up times	Mean Age, Patients and Implants (N)	Systemic, periodontal status, smoking habits	Time of loading in relation to implant placement	Location	Site, setting and funding
Bolle <i>et al.</i> 2018. (30)	RCT 1 year post-loading	Mean age: CG 56.4 (36-71); SG 60.75 (25-77) Patients n= 40 (CG 20; SG 20) Implants n= 78 (CG 41; SG 37)	Systemic and periodontal health; non-smokers, moderate smokers (<10 cig/day), or heavy smokers (>10 cig/day)	4 months with provisional prosthesis, and after another 4 months with definitive prosthesis	Post. Max	Italy, University Hospital, private centers, Public Hospital; partially supported by Global D (Brignais, France)
Gastaldi <i>et al.</i> 2018. (31)	RCT 1, 3 years post-loading	Mean age: CG 58.5 (45-75); SG 61.1 (45-70) Patients n= 40 (CG 20; SG 20) Implants n= 73 (CG 37; SG 36)	Systemic and periodontal health; non-smokers, moderate smokers (<10cig/day), or heavy smokers (>10cig/day)	4 months with provisional prosthesis, and after another 4 months with definitive prosthesis	Post. Max	Italy, University Hospital, private centers, Public Hospital: partially supported by MegaGen Implant (South Korea)
Hadzik <i>et al.</i> 2018. (32)	RCT After surgery, 6 months and 12 months	Mean age: 45,5 y Patients n= 29 (CG 15; SG 14) Implants n= 29 (CG 15; GS 14)	≤ 25 plaque index, no smockers, no bruxers	36 months since implant placement, 30 months since loading	Post. Max	-
Thoma <i>et al.</i> 2018. (33)	RCT 1, 3, 5 years post-loading	Mean age 20-75 years Patients n=90 (CG 46; SG 44) Implants n= 124 (CG 64; SG 60)	Systemic and periodontal health; non-smokers, moderate smokers (<10 cig/day), or heavy smokers (>10 cig/day)	6 months	Post. Max	Austria, Switzerland, Poland, Spain, USA, private centers; fully funded by Dentsply Implants, (Mölnådal, Sweden)
Bechara <i>et al.</i> 2017. (34)	RCT 1, 3 years post-loading	Mean age: 48.1 \pm 15.1 years Patients n= 53 (CG 20; SG 33) Implants n= 90 (CG 45; SG 45)	Systemic and periodontal health; non-smokers, moderate smokers (<10 cig/day), or heavy smokers (>10 cig/day). Bruxism was an exclusion criteria	4 months	Post. Max	Lithuanian University; no funding support reported
Esposito <i>et al.</i> 2014. (35)	RCT 1, 3 years post-loading	Mean age: 56 (45-70) Patients n= 15 Implants n= 72 (CG 38; SG 34)	Systemic and periodontal health; non-smokers, moderate smokers (<10 cig/day), or heavy smokers (>10 cig/day).	4 months with provisional prosthesis, and after another 4 months with definitive prosthesis	Post. Max	Italy, private centers, Public Hospital; partially supported by MegaGen Implant (Gyeongbuk, South Korea)
Guljé <i>et al.</i> 2014. (36)	RCT 1 year	Mean age: 50 \pm 10,1 (SG) , 48 \pm 8,9 (CG) Patients n= 41 (CG 20, SG 20) Implants n= 72 (CG 20; SG 20)	Systemic and periodontal health; non-smokers, moderate smokers (<10 cig/day), Controlled DM, no corticosteroids, no chemoteraphy in the previous 5 years, no radiation, no systemic or local disease that compromise the treatment	12 months with definitive prosthesis	Post. Max	Twentyone patients were treated in the centre in Apeldoorn and 20 patients were treated in the centre in Groningen
Pistilli <i>et al.</i> 2013. (37)	RCT 12 months post-loading	Mean age: 57.6 (45-80) Patients n= 20 Implants n= 83 (CG 44; SG 39)	Systemic and periodontal health; non-smokers, moderate smokers (<10 cig/day), or heavy smokers (>10 cig/day).	4 months with provisional prosthesis, and after another 4 months with definitive prosthesis	Post. Max	Italy, University Hospital, private centers, Public Hospital; partially supported by TecnoSS®, (Giaveno, Italy) and Southern Implants

Note.CG: control group (longer implants [≥ 8 mm] simultaneously o deferred lateral sinus floor elevation. SG: study group (short implant <8 mm)

The selection of RCTs included a total of 328 patients (although Esposito *et al.* (35) and Pistilli *et al.*(37) did not reported the number of patients in each group), with a total of 621 implants (296 allocated to study group, and 316 to control group). Six studies only investigated partially edentulous patients (30-33,35,37); only two

studies employed a split-mouth design (34,35), while the rest had parallel treatment arms (Table 3).

- Quality assessment

Table 4 summarizes the results of bias risk assessment in the included RCTs and The Cochrane Risk of Bias Tool for Randomized Controlled Trials criteria.

Table 3: General characteristics of the intervention and results.

Study design	Follow-up	Preoperative preparation	CG LSFE / implant length	SG short implant length	RBH (mm)	Bone graft/ Membrane (CG)	Post-surgical treatment/ Post-op instructions	Survival rate (%)	Complications	MBL (mm)	Authors conclusion
Bolle <i>et al.</i> 2018. (30)	1 year	CBCT, OHI, prophylactic ATB 1h before, CHX 0.2% 1 minute	Simultaneous/>10 mm	4 mm	4-5 mm	Particulated porcine bone/ resorbable collagen membrane	Amoxicillin 1gr twice/day/7days, NSAID (Ibuprofen 400 mg) 2 to 4 times/day, soft diet, not allowed to wear removable prosthesis up to 1 month	CG= 90.2% SG= 94.6%	CG= 14 Intra-operative= 3 Post-operative=11 (Biological=9; Prosthetic=2) SG= 4 Intra-operative= 0 Post-operative= 4 (Biological=2; Prosthetic=2)	CG= 0.72±0.25 SG= 0.63±0.15	One year after loading, 4.0 mm long implants achieved similar results to longer implants in augmented jaws, but fewer complications
Gastaldi <i>et al.</i> 2018. (31)	3 years	CBCT, OHI, prophylactic ATB 1h before, CHX 0.2% 1 minute	Simultaneous/>10 mm	5 mm	4-6 mm	Particulated porcine bone/ resorbable collagen membrane	Amoxicillin 1gr twice/day/7days, NSAID (Ibuprofen 400 mg) 2 to 4 times/day, CHX gel, soft diet, avoid brushing and trauma at surgical site.	CG= 100% SG=97.2%	CG=6 Intra-operative= 5 Post-operative= 1 (Biological=0; Prosthetic=1) SG= 4 Intra-operative= 0 Post-operative= 2 (Biological=0; Prosthetic=2)	CG= 1.79±0.59 SG= 1.34±0.35	Three years after loading 5.0 mm × 5.0 mm implants achieved similar results to longer implants with GBR
Hadzik <i>et al.</i> 2018. (32)	3 years	OHI, Prophylactic ATB	Simultaneous 11 and 13 mm	6mm	6 mm heigh 6-7mm widht	Xenogenic Bone Graft	0,12% clo-rhexidine solution, ATB and Analgesics (non specified)	CG: 100% SG = 100%	-	CG= 0,34 ±0,24mm SG= 0,22±0,46mm	Short implants can be successfully used to support single crowns in the lateral part of the maxilla
Thoma <i>et al.</i> 2018. (33)	5 years	Prophylactic ATB 1h before, CHX 0.2% 1 minute	Simultaneous 11-15 mm	6 mm	5-7 mm	Particulated bovine bone mixed with autogenous bone chips/ resorbable collagen membrane	NP	CG=100% SG=98,5%	CG=24 Intra-operative= 1 Post-operative= 23 (Biological=9; Prosthetic=14) SG= 28 Intra-operative= 2 Post-operative=26 (Biological=5; Prosthetic=21)	CG= 0.46±1 SG= 0.54±0.87	Short implants (6 mm) for single-tooth restorations in the posterior maxilla as a viable solution versus longer implants in combination with sinus lift.

Table 3 cont.: General characteristics of the intervention and results.

Bechara <i>et al.</i> 2017. (34)	3 years	CBCT, OPG, prophylactic ATB 1h before, CHX 0.2% 1 minute	Simultaneous >10 mm	6 mm	≥4 mm	Collagenated porcine particulate bone graft/ Pericardium porcine resorbable collagen membrane	OHI, Amoxicillin 500mg plus clavulanic acid, NSAID (Ibuprofen 600mg), CHX 0.2% for 2 week, not allowed to wear removable dentures up to 1 month postoperative	CG=95.6% SG=100%	CG=19 Intra-operative= 3 Post-operative=17 (Biological=17; Prosthetic=0) SG= 0	CG= 0.27±(0.232-0.313) SG= 0.20±(0.166-0.236)	At three years short (6-mm) dental implants and longer (≥10-mm) dental implants in combination with sinus floor elevation provided good results. However, with short implants, the treatment was faster and less expensive.
Espósito <i>et al.</i> 2014. (35)	3 years	CBCT, OHI, prophylactic ATB 1h before, CHX 0.2% 1 minute	Simultaneous >10 mm	5 mm	4-6 mm	Particulated bovine bone/ resorbable collagen membrane	Amoxicillin 1gr twice/ day/7days, NSAID (Ibuprofen 400 mg) 2 to 4 times/day, CHX gel, soft diet.	CG=97.36% SG=91.17%	CG=1 Intra-operative= 1 Post-operative= 0 SG= 4 Intra-operative= 3 Post-operative=1 (Biological=1; Prosthetic=0)	CG= 1.54±0.35 SG= 1.02±0.47	Both techniques provided acceptable results up to 3 years after loading. However, with 5-mm implants treatment was faster and cheaper.
Guljé <i>et al.</i> 2014. (36)	1 year	CBCT, OPG, Prophylactic ATB 1 hour before,	Simultaneous 11mm	6mm	6-8 mm	Autologous bone + Particulated bovine bone + collagen membrane	Clorhexidine mouthrinse	CG= 100% SG= 100%	CG=0 Intra-operative= 0 Post-operative= 0 SG= 0 Intra-operative= 0 Post-operative=0 (Biological=0; Prosthetic=0)	CG= 0,1 ±0,3mm SG= 0,1±0,2mm	6-mm implants and 11-mm implants combined with sinus floor elevation surgery are equally successful to support a single crown in the resorbed posterior maxilla after 1-year follow-up
Pistilli <i>et al.</i> 2013. (37)	1 year	CBCT, OHI, prophylactic ATB 1h before, CHX 0.2% 1 minute	Simultaneous >10 mm	6 mm	5-7 mm	Particulated porcine bone/ resorbable collagen membrane	Amoxicillin 1gr twice/ day/7days, NSAID (Ibuprofen 400 mg) 2 to 4 times/day, CHX 0.2% for 2 week, soft diet for 1 week, to avoid brushing and trauma at surgical site	CG=100% SG=100%	CG=4 Intra-operative= 4 Post-operative= 0 SG= 0	CG= 1.09±0.05 SG= 1.02±0.06	6 mm-long implants achieved similar results to longer implants placed in augmented bone.

Note. CBCT: Cone Beam Computed Tomography. OHI: Oral Hygiene Instruction. LSFE: lateral sinus floor elevation. NSAID: Non-Steroidal Anti-Inflammatory Drugs. CG: control group (longer implants [≥8mm] simultaneously or deferred lateral sinus floor elevation). SG: study group (short implants <8 m

Table 4: Bias risk assessment for the included RCTs using The Cochrane Risk of Bias Tool for Randomized Controlled Trials.

Study	Random sequence generation	Allocation concealment	Blinding of participants and personnel	Blinding of outcome assessment	Incomplete outcome data addresses	Selective reporting	Other bias	Overall risk of bias
Bolle <i>et al.</i> 2018 (3)	Low	Low	High	Low	Low	Low	Low	Moderate
Gastaldi <i>et al.</i> 2018 (31)	Low	Low	High	Low	Low	Low	Low	Moderate
Hadzik <i>et al.</i> 2018 (32)	Low	Low	Low	NP	Low	Low	Low	Low
Thoma <i>et al.</i> 2018 (33)	Low	Low	Low	NP	Low	Low	Low	Low
Bechara <i>et al.</i> 2017 (34)	Low	Low	NP	Low	Low	Low	Low	Low
Espósito <i>et al.</i> 2014 (35)	Low	High	NP	Low	Low	Low	Low	Moderate
Guljé <i>et al.</i> 2014 (36)	Low	Low	NP	NP	Low	Low	Low	Low
Pistilli <i>et al.</i> 2013 (37)	Low	High	High	Low	Low	Low	Low	High

- Survival rate

A random-effects model was used to assess the survival rate of implants; statistically significant heterogeneity was not found among the publications ($I^2=0\%$; $p=0.81$). The test for overall effect showed no statistically significant differences in the survival rate of short implants (<8mm) compared to longer implants (≥ 8 mm) with lateral sinus floor elevation (Risk Ratio [RR] of 0.108; 95% CI: [0.42-2.83]; $p=0.8$) (Fig. 2).

- Marginal Bone Loss

The random-effect model showed highly significant heterogeneity between the studies ($I^2=97.9\%$; $p=0.00$). The overall effect test showed statistically significant differences in marginal bone loss between control and study groups ($p=0.026$). A RR of 0.86; 95% CI: [0.75, 0.98] in favor of short implants (<8mm) (Fig. 2). This finding implies that the risk of marginal bone loss in patients receiving longer implants (≥ 8 mm) with lateral sinus floor elevation is significantly higher than patients receiving short implants (<8mm). However, these results should be treated with caution due to the different follow-up periods among the studies analyzed.

- Complications

The test for overall effect did not find statistical significance (RR of 0.60; 95% CI: [0.25-1.47]; $p=0.262$). For this variable the random-effects model showed a statistically significant heterogeneity between the studies ($I^2=60.2\%$; $p=0.03$) (Fig. 2). So, complications were divided into four groups: (3a) intra-operative complications; (3b) post-operative complications; (3c) biological

complications; and (3d) prosthetic complications.

Intra-operative complications:

The Chi² test showed homogeneity between the studies ($I^2=22.9\%$ $p=0.33$); and the overall effect test found no statistically significant differences between control and study groups (RR of 0.51; 95% CI: [0.16-1.63]; $p=0.258$), in relation to intra-operative complications (Fig. 3).

Post-operative complications:

The Chi² test showed homogeneity between the studies ($I^2=36.1\%$ $p=0.15$); and the overall effect test found no statistically significant differences between control and study groups (RR of 0.76; 95% CI: [0.33-1.74]; $p=0.517$), in relation to post-operative complications (Fig. 3).

Biological complications:

The Chi² test did not find statistically significant heterogeneity between the studies ($I^2=0.0\%$; $p=0.43$). The overall effect test demonstrated that there were more biological complications in the control group (RR of 0.46; 95% CI: [0.22-0.95]; $p=0.037$) (Fig. 3).

Prosthetic complications

The Chi² test demonstrated homogeneity between the studies ($I^2=0.0\%$ $p=1.00$); and the overall effect test didn't find statistically significant differences between the control and study groups ($p=0.110$). A high number of studies did not suffer any prosthetic complications, either for short implant groups or longer implant groups. A RR of 1.52; 95% CI: [0.91, 2.54] favored the control group slightly (Fig. 3).

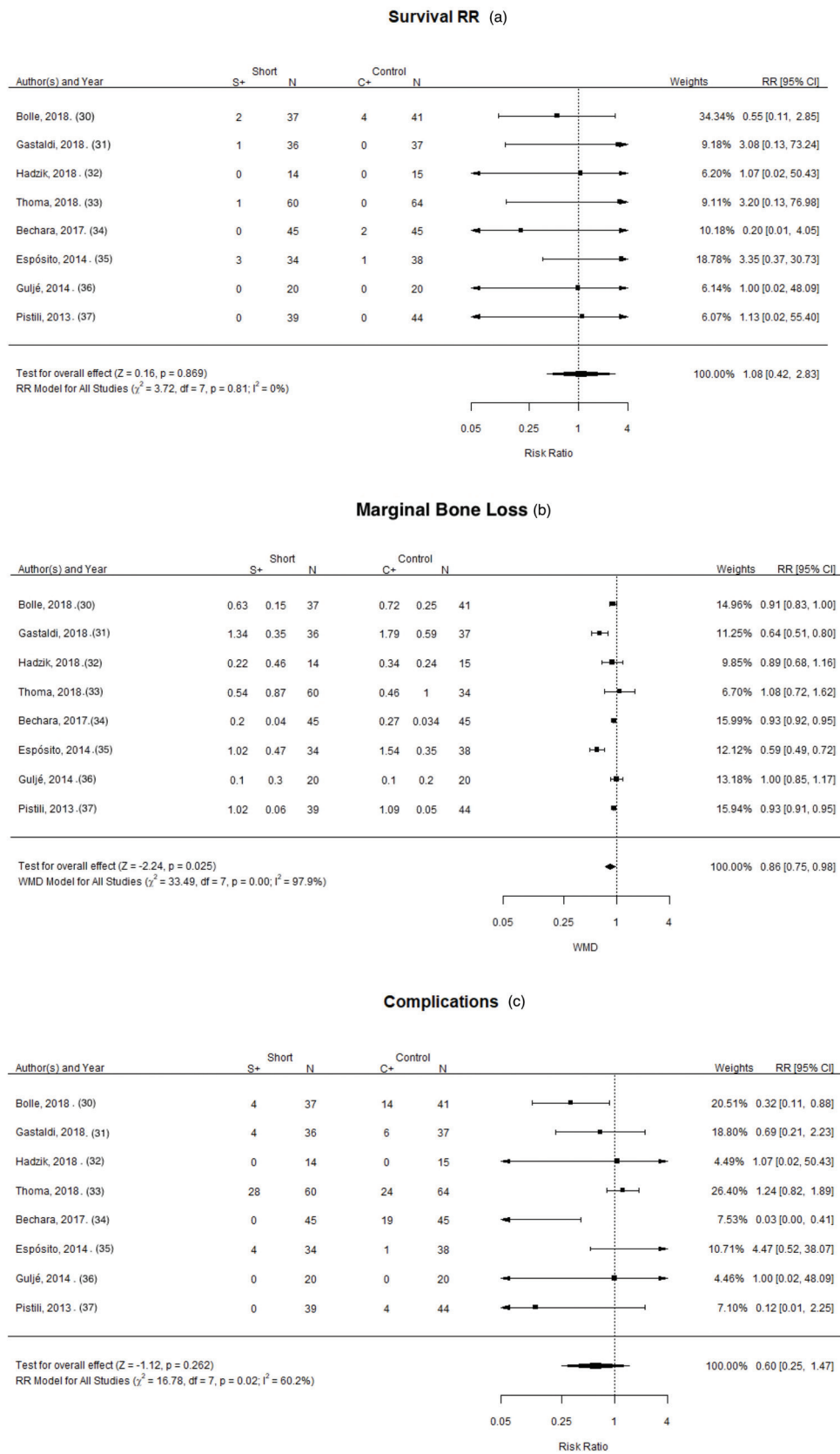


Fig. 2: Forest plot for the event: (a) “implant survival rate; (b) “marginal bone loss”; (c) “complications”.

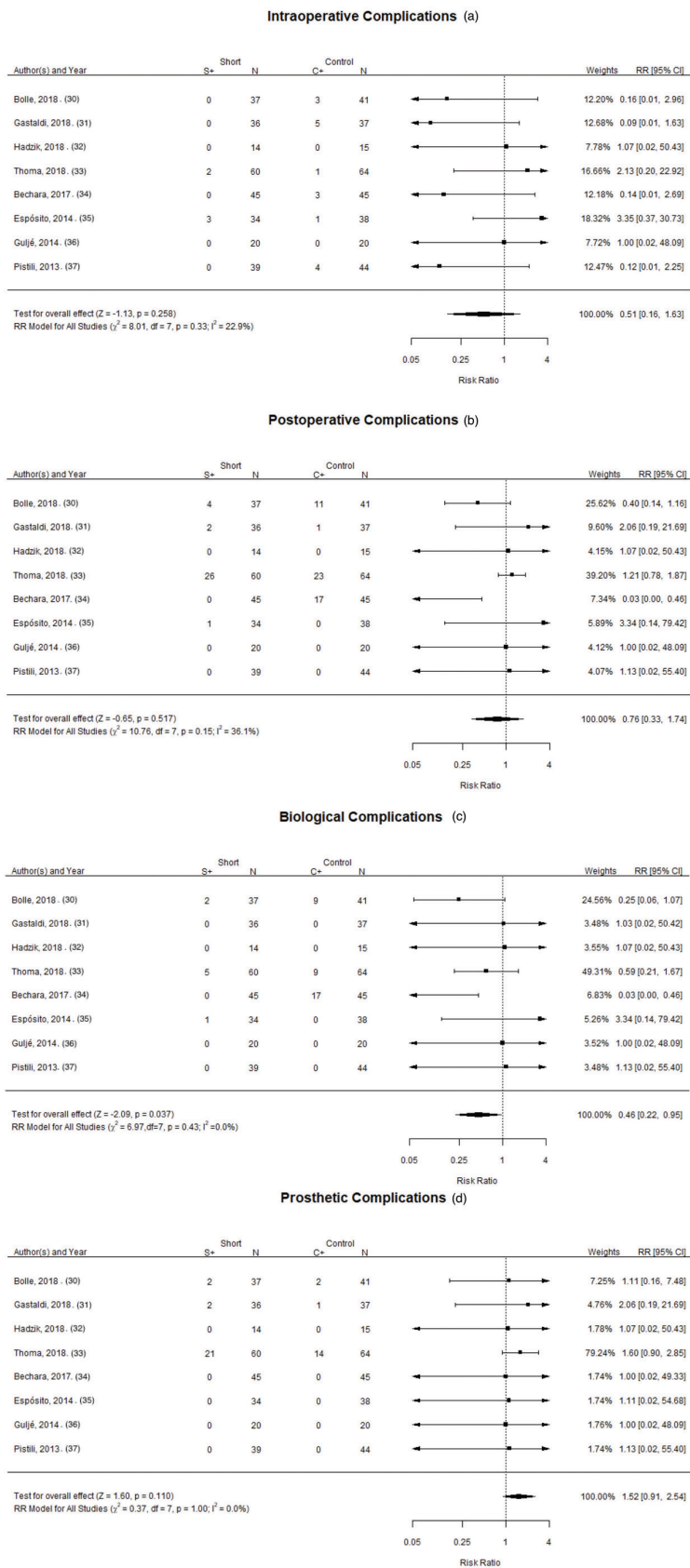


Fig. 3: Forest plot for the event: (a) “intra-operative complications”; (b) “post-operative complications”; (c) “biological complications”; (d) “prosthetic complications”.

Discussion

Short implants are considered a reliable and predictable alternative to bone augmentation procedures (7,11,13), reducing the rate of complications, intra-operative time, patient morbidity, and treatment costs (12). The fourth European Association for Osseointegration (EAO) consensus conference (31) reported a survival rate of 99.0% for short implants (<8 mm) after 16-18 months follow-up, considering their use a routine treatment. The present systematic review and meta-analysis defined the term 'short' to describe implants of less than 8 mm (<8 mm) in length in accordance with the definition proposed recently by Plonka *et al.* [2018] (11).

- Survival rate

The results of meta-analysis did not find statistically significant differences in survival rates between short implants (<8mm) and longer implants (\geq 8mm) with lateral sinus floor elevation. None of the RCTs analyzed reported statistically significant differences between control and test groups. Similar results were reported by Hadzik *et al.* (32), Guljé *et al.* (36) and Pistilli *et al.* (37), who obtained 100% survival rates for both control and test implants. However, these results should be treated with caution because of the small numbers of failed implants in both groups and the short follow-up periods.

Short implants might be expected to suffer more failures than long implants after loading because of their bio-mechanical disadvantages. However, the results of the RCTs in this review did not demonstrate this effect. The high survival rate of short implants could be attributed to improved implant surfaces and connections. Traditionally, machined surface implants with external connections were used, but the development of internal connections and rough surfaces have increased the implants surface area, favoring bone-to-implant contact, reduced treatment time, implant diameter and length, so that they now produce similar or even better results in comparison with machined implants (38).

The length of the implants included in the study groups ranged between 4 mm and <8 mm. Anitua *et al.* (38) obtained a 98.2% survival rate for 114 extra-short implants (<6.5 mm) after a follow-up period of 26 months. Recently, Srinivasan *et al.* (39), 690 6-mm short implants were assessed, obtaining a cumulative survival rate of 93.7% for maxillary implants and 98.6% for maxillary and mandibular implants together.

Furthermore, in a retrospective study published by Tetsch *et al.* (11) showed implants of \geq 10 mm with lateral sinus floor elevation had 98.3% implant survival rate after 15.5 years of follow-up.

- Complications

In reference to complications, two studies (30,34) reported statistically significant differences in favor of short implants, although the random-effects model showed statistically significant heterogeneity between

studies. For this reason, complications were divided into four groups: 1) intra-operative complications; 2) post-operative complications: 2a) biological complications; and 2b) prosthetic complications. When complications were divided into subgroups, only Bechara *et al.* (34) reported a significantly higher number of post-operative biological complications in the control group. The complications associated with longer implants with lateral maxillary sinus augmentation were, in order of frequency: pain/swelling > sinus membrane perforation > nasal bleeding and post-operative headache > intra-operative bleeding > infection of the grafting material > migration of the implant into sinus maxillary sinus. In the group of short implants (<8 mm) the most frequent complications were: sinus membrane perforation > nasal bleeding > migration of the implant into sinus maxillary sinus.

The most common prosthetic complication in both groups was screw loosening/fracture. In brief, incidence was slightly higher in study groups (short implants) although the difference was not statistically significant. Only a few studies reported prosthetic complications, comparing study groups with control groups, but the higher number of implants in the control groups suggest that longer implants (>8mm) with lateral sinus floor elevation suffered fewer prosthetic complications.

- Marginal Bone Loss (MBL)

In the present study, MBL in patients receiving longer implants (\geq 8mm) with lateral sinus floor elevation was statistically higher compared with patients who received short implants (<8mm).

This results can be justified by the article of Galindo-Moreno *et al.* (40), evaluated the MBL of implants placed in native bone or in grafted sinus lift in the maxilla. Concluded that "implants placed in sites that received maxillary sinus augmentation exhibited more marginal bone loss than implants placed in pristine bone, although marginal bone loss mainly occurred during the first 12 months after functional loading".

In the RCT by Bechara *et al.* (34), the study group included short implants (6 mm in length) placed in healed sites and post-extraction sockets; however, no statistically significant differences in MBL between the two groups were found at either 1- or 3-year follow ups.

Due to the heterogeneity of the publications reviewed and the lack of information this systematic review suffered some limitations. Three out eight reviewed publications were considered with high risk of bias what might affect the obtained results. Furthermore, it was not possible to draw any definitive conclusions regarding the success rate, impact of implant diameter, implant design, and the type of prosthetic restoration on the variables investigated. Little information was available in the studies reviewed regarding the type of prosthetic reconstruction (single unit or multiple units),

number of prosthetic reconstructions, and the number of implants per prosthetic unit. Moreover, the outcomes of the present review should be interpreted with caution given the small sample size and short follow-up times of the studies analyzed. In addition, five (30,33-35,37) out the 8 papers analyzed were published by the same research team.

Conclusions

Within the limitations of the present systematic review, prosthetic rehabilitations with short implants (<8mm) in the maxillary posterior areas are a predictable treatment option as an alternative to sinus floor elevation. No statistically significant differences in the survival rate and complications were found between short (<8mm) and longer implants (\geq 8mm) with lateral sinus floor elevation. Nevertheless, longer implants (\geq 8mm) in combination with lateral sinus elevation presented significantly greater marginal bone loss.

References

- Velasco-Torres M, Padial-Molina M, Avila-Ortiz G, Garcia-Delgado R, O'Valle F, Catena A, *et al.* Maxillary sinus dimensions decrease as age and tooth loss increase. *Implant Dent.* 2017;26:288-95.
- Tan WC, Lang NP, Zwahlen M, Pjetursson BE. A systematic review of the success of sinus floor elevation and survival of implants inserted in combination with sinus floor elevation. Part II: transalveolar technique. *J Clin Periodontol.* 2008;35:241-54.
- Wang HL, Katranji A. ABC sinus augmentation classification. *Int J Periodontics Restorative Dent.* 2008;28:383-9.
- Özkan Y, Akoğlu B, Kulak-Özkan Y. Maxillary Sinus Floor Augmentation Using Bovine Bone Grafts With Simultaneous Implant Placement: A 5-Year Prospective Follow-Up Study. *Implant Dent.* 201;20:455-9
- Tetsch J, Tetsch P, Lysek DA. Long-term results after lateral and osteotome technique sinus floor elevation: a retrospective analysis of 2190 implants over a time period of 15 years. *Clin Oral Implants Res.* 2010;21:497-503.
- Erdem NF, Çiftçi A, Acar AH. Three-Year Clinical and Radiographic Implant Follow-up in Sinus-Lifted Maxilla With Lateral Window Technique. *Implant Dent.* 2016;25:214-21.
- Lozano-Carrascal N, Salomé-Coll O, Gehrke SA, Calvo-Guirado JL, Hernández-Alfaro F, Gargallo-Albiol J. Radiological evaluation of maxillary sinus anatomy: A cross-sectional study of 300 patients. *Ann Anat.* 2017;214:1-8.
- Galindo-Moreno P, Padial-Molina M, Avila G, Rios HF, Hernández-Cortés P, Wang HL. Complications associated with implant migration into the maxillary sinus cavity. *Clin Oral Implants Res.* 2012; 23:1152-60.
- Moreno Vazquez JC, Silván González A, Serrano Gil H, Santamaria Misfust R. Complication rate in 200 consecutive sinus lift procedures: guidelines for prevention and treatment. *J Oral Maxillofac Surg.* 2014;72:892-901.
- Monje A, Chan HL, Fu JH, Suarez F, Galindo-Moreno P, Wang HL. Are Short Dental Implants (<10mm) Effective? A Meta-Analysis on Prospective Clinical Trials. *J Periodontol.* 2013 ;84:895-904.
- Plonka AB, Urban IA, Wang HL. Decision Tree for Vertical Ridge Augmentation. *Int J Periodontics Restorative Dent.* 2018;38:269-75.
- Neldam CA, Pinholt EM. State of the Art of Short Dental Implants: A Systematic Review of the Literature. *Clin Implant Dent Relat Res.* 2012;14:622-32.
- Esposito M, Cannizzaro G, Soardi E, Pellegrino G, Pistilli R, Felice P. A 3-year post-loading report of a randomised controlled trial on the rehabilitation of posterior atrophic mandibles: short implants

or longer implants in vertically augmented bone?. *Eur J Oral Implantol.* 2011;4:301-11.

- Moher D, Liberati A, Tetzlaff J, Altman DG; PRISMA Group. Preferred reporting items for systematic reviews and meta-analyses: the PRISMA statement. *J Clin Epidemiol.* 2009;62:1006-12.
- Cannizzaro G, Felice P, Leone M, Viola P, Esposito M. Early loading of implants in the atrophic posterior maxilla: lateral sinus lift with autogenous bone and Bio-Oss versus crestal mini sinus lift and 8-mm hydroxyapatite-coated implants. A randomized controlled clinical trial. *Eur J Oral Implantol.* 2009;2:25-38.
- Cannizzaro G, Felice P, Minciarelli AF, Leone M, Viola P, Esposito M. Early implant loading in the atrophic posterior maxilla: 1-stage lateral versus crestal sinus lift and 8 mm hydroxyapatite-coated implants. A 5-year randomised controlled trial. *Eur J Oral Implantol.* 2013;6:13-25.
- Esposito M, Barausse C, Pistilli R, Sammartino G, Grandi G, Felice P. Short implants versus bone augmentation for placing longer implants in atrophic maxillae: One-year post-loading results of a pilot randomised controlled trial. *Eur J Oral Implantol.* 2015;8:257-68.
- Taschieri S, Lolato A, Testori T, Francetti L, Del Fabbro M. Short dental implants as compared to maxillary sinus augmentation procedure for the rehabilitation of edentulous posterior maxilla: Three-year results of a randomized clinical study. *Clin Implant Dent Relat Res.* 2018;20:9-20.
- Felice P, Checchi V, Pistilli R, Scarano A, Pellegrino G, Esposito M. Bone augmentation versus 5-mm dental implants in posterior atrophic jaws. Four-month post-loading results from a randomised controlled clinical trial. *Eur J Oral Implantol.* 2009;2:267-81.
- Esposito M, Cannizzaro G, Soardi E, Pistilli R, Piattelli M, Corvino V, *et al.* Posterior atrophic jaws rehabilitated with prostheses supported by 6 mm-long, 4 mm-wide implants or by longer implants in augmented bone. Preliminary results from a pilot randomised controlled trial. *Eur J Oral Implantol.* 2012;5:19-33.
- Esposito M, Barausse C, Pistilli R, Checchi V, Diazi M, Gatto MR, *et al.* Posterior jaws rehabilitated with partial prostheses supported by 4.0 x 4.0 mm or by longer implants: Four-month post-loading data from a randomised controlled trial. *Eur J Oral Implantol.* 2015;8:221-30.
- Esposito M, Zucchelli G, Barausse C, Pistilli R, Trullenque-Eriksson A, Felice P. Four mm-long versus longer implants in augmented bone in atrophic posterior jaws: 4-month post-loading results from a multicenter randomised controlled trial. *Eur J Oral Implantol.* 2016;9:393-409.
- Pistilli R, Felice P, Piattelli M, Gessaroli M, Soardi E, Barausse C, *et al.* Posterior atrophic jaws rehabilitated with prostheses supported by 5x5 mm implants with a novel nanostructured calcium-incorporated titanium surface or by longer implants in augmented bone. One-year results from a randomised controlled trial. *Eur J Oral Implantol.* 2013;6:343-57.
- Thoma DS, Haas R, Tutak M, Garcia A, Schincaglia GP, Hammerle CH. Randomized controlled multicenter study comparing short dental implants (6 mm) versus longer dental implants (11-15 mm) in combination with sinus floor elevation procedures. Part I: demographics and patient-reported outcomes at 1 year of loading. *J Clin Periodontol.* 2015;42:72-80.
- Esposito M, Pellegrino G, Pistilli R, Felice P. Rehabilitation of posterior atrophic edentulous jaws: prostheses supported by 5 mm short implants or by longer implants in augmented bone? One-year results from a pilot randomised clinical trial. *Eur J Oral Implantol.* 2011;4:21-30.
- Felice P, Checchi L, Barausse C, Pistilli R, Sammartino G, Masi I, *et al.* Posterior jaws rehabilitated with partial prostheses supported by 4.0 x 4.0 mm or by longer implants: One-year post-loading results from a multicenter randomised controlled trial. *Eur J Oral Implantol.* 2016;9:35-45.
- Felice P, Pistilli R, Barausse C, Bruno V, Trullenque-Eriksson A, Esposito M. Short implants as an alternative to crestal sinus lift: A 1-year multicentre randomised controlled trial. *Eur J Oral Implantol.* 2015;8:375-84.

28. Zhang XM, Shi JY, Gu YX, Qiao SC, Mo JJ, Lai HC. Clinical Investigation and Patient Satisfaction of Short Implants Versus Longer Implants with Osteotome Sinus Floor Elevation in Atrophic Posterior Maxillae: A Pilot Randomized Trial. *Clin Implant Dent Relat Res.* 2017;19:161-6.
29. Yu H, Wang X, Qiu L. Outcomes of 6.5-mm Hydrophilic Implants and Long Implants Placed with Lateral Sinus Floor Elevation in the Atrophic Posterior Maxilla: A Prospective, Randomized Controlled Clinical Comparison. *Clin Implant Dent Relat Res.* 2017;19:111-22.
30. Bolle C, Felice P, Barausse C, Pistilli V, Trullenque-Eriksson A, Esposito M. 4 mm long vs longer implants in augmented bone in posterior atrophic jaws: 1-year post-loading results from a multicentre randomised controlled trial. *Eur J Oral Implantol.* 2018;11:31-47.
31. Gastaldi G, Felice P, Pistilli V, Barausse C, Ippolito DR, Esposito M. Posterior atrophic jaws rehabilitated with prostheses supported by 5 × 5 mm implants with a nanostructured calcium-incorporated titanium surface or by longer implants in augmented bone. 3-year results from a randomised controlled trial. *Eur J Oral Implantol.* 2018;11:49-61.
32. Hadzik J, Krawiec M, Kubasiewicz-Ross P, Prylińska-Czyżewska A, Gedrange T, Dominiak M. Short Implants and Conventional Implants in The Residual Maxillary Alveolar Ridge: A 36-Month Follow-Up Observation. *Med Sci Monit.* 2018;24:5645-52.
33. Thoma DS, Haas R, Sporniak-Tutak K, Garcia A, Taylor TD, Hammerle CHF. Randomized controlled multicentre study comparing short dental implants (6 mm) versus longer dental implants (11–15 mm) in combination with sinus floor elevation procedures: 5-Year data. *J Clin Periodontol.* 2018;45:1465-74.
34. Bechara S, Kubilius R, Veronesi G, Pires JT, Shibli JA, Manganano FG. Short (6-mm) dental implants versus sinus floor elevation and placement of longer (≥10-mm) dental implants: a randomized controlled trial with a 3-year follow-up. *Clin Oral Implants Res.* 2017;28:1097-107.
35. Esposito M, Pistilli R, Barausse C, Felice P. Three-year results from a randomised controlled trial comparing prostheses supported by 5-mm long implants or by longer implants in augmented bone in posterior atrophic edentulous jaws. *Eur J Oral Implantol.* 2014;7:383-95.
36. Guljé FL, Raghoebar GM, Vissink A, Meijer HJ. Single crowns in the resorbed posterior maxilla supported by either 6-mm implants or by 11-mm implants combined with sinus floor elevation surgery: a 1-year randomised controlled trial. *Eur J Oral Implantol.* 2014;7:247-55.
37. Pistilli R, Felice P, Cannizzaro G, Piatelli M, Corvino V, Barausse C, *et al.* Posterior atrophic jaws rehabilitated with prostheses supported by 6 mm long 4 mm wide implants or by longer implants in augmented bone. One-year post-loading results from a pilot randomised controlled trial. *Eur J Oral Implantol.* 2013;6:359-72.
38. Anitua E, Alkhraisat MH, Orive G. Novel technique for the treatment of the severely atrophied posterior mandible. *Int J Oral Maxillofac Implants.* 2013;28:1338-46.
39. Srinivasan M, Vazquez L, Rieder P, Moraguez O, Bernard JP, Belser UC. Survival rates of short (6 mm) micro-rough surface implants: a review of literature and meta-analysis. *Clin Oral Implants Res.* 2014;25:539-45.
40. Galindo-Moreno P, Fernández-Jiménez A, Avila-Ortiz G, Silvestre FJ, Hernández-Cortés P, Wang HL. Marginal bone loss around implants placed in maxillary native bone or grafted sinuses: a retrospective cohort study. *Clin Oral Implants Res.* 2014;25:378-84.

Acknowledgements

The authors would like to thank Alex Romero Honrubia for his valuable contribution to the statistical work and its continuous evaluation.

Funding

The present investigation has not been partially or fully financially supported.

Conflict of interest

The authors declare no conflict of interest.