

ORIGINAL ARTICLE

Predictors of periapical bone healing associated with teeth having large periapical lesions following nonsurgical root canal treatment or retreatment: A cone beam computed tomography-based retrospective study

Carolina Mosquera-Barreiro¹  | Manuel Ruíz-Piñón¹  | Francesc Abella Sans²  |
Venkateshbabu Nagendrababu³  | Thilla Sekar Vinothkumar⁴  |
Jenifer Martín-González⁵  | Benjamín Martín-Biedma⁶  | Pablo Castelo-Baz⁶ 

¹Surgery and medical surgical specialties. International theoretical-practical Master of Endodontics, Dentistry Restorative and Aesthetics, University of Santiago de Compostela, Santiago de Compostela, Spain

²Department of Endodontics, Universitat Internacional de Catalunya, Barcelona, Spain

³Department of Preventive and Restorative Dentistry, University of Sharjah, College of Dental Medicine, Sharjah, United Arab Emirates

⁴Department of Restorative Dental Sciences, Division of Operative Dentistry, College of Dentistry, Jazan University, Jazan, Saudi Arabia

⁵Endodontic Section, Department of Stomatology, School of Dentistry, University of Sevilla, Sevilla, Spain

⁶Oral Sciences Research Group, Endodontics and Restorative Dentistry Unit, School of Medicine and Dentistry, University of Santiago de Compostela, Health Research Institute of Santiago de Compostela (IDIS), Santiago de Compostela, Spain

Correspondence

Benjamín Martín-Biedma, Oral Sciences Research Group, Endodontics and Restorative Dentistry Unit,

Abstract

Aim: Several factors influence the condition of the periapical tissues associated with root filled teeth. The primary objective of this study was to retrospectively evaluate the extent and speed of bone healing of large periapical lesions associated with nonsurgical root canal treatment or retreatment. The secondary objective was to analyse the relationship between the time to complete healing when analysed using cone beam computed tomography (CBCT) and other possible predictors that affect healing.

Methodology: Seventy-nine patients were treated during the years 2013–2020 with large periapical lesions of endodontic origin (10–15 mm) as observed on intraoral periapical radiographs (IOPAR) were included. IOPAR and CBCT were available before treatment and during the follow-up (IOPAR every 6 months and CBCT every 12 months). The volume of periapical lesions was calculated by OsiriX Lite software. Variables such as initial volume of the lesion, age, gender, type of treatment or type of root canal filling were compared to identify the differences between healed and unhealed lesions. Pearson's Chi-square test was used for categorical variables, the t-test for age and the Wilcoxon test for initial volume of the lesion. The association between time to healing and the variables was assessed using univariate analysis and multivariate analysis. The Wilcoxon test was used to observe the association of healing time with categorical variables and the correlation index was measured with the quantitative variables.

Results: Of the 79 cases analysed, 60 lesions (76%) were completely healed as verified by CBCT in a mean healing time of 19 months, of which 60% healed fully between 12 and 18 months. Increase in age of patient and larger initial volume of the lesion were associated with a significantly longer healing time ($p < .001$). Gender, filling material and type of treatment did not have a significant effect on the healing process ($p > .05$).

This is an open access article under the terms of the [Creative Commons Attribution](https://creativecommons.org/licenses/by/4.0/) License, which permits use, distribution and reproduction in any medium, provided the original work is properly cited.

© 2023 The Authors. *International Endodontic Journal* published by John Wiley & Sons Ltd on behalf of British Endodontic Society.

School of Medicine and Dentistry,
University of Santiago de Compostela,
Health Research Institute of Santiago
de Compostela (IDIS), Santiago de
Compostela 15706, Spain.
Email: benjamin.martin@usc.es

Conclusions: Clinicians should be aware that periapical lesions in older patients and larger areas of bone loss take longer to heal. CBCT monitoring of large periapical lesions is critical and it can help clinicians in the decision-making process.

KEYWORDS

cone beam computed tomography, follow-up, periapical healing, root canal treatment

INTRODUCTION

Apical periodontitis (AP) is a chronic inflammatory condition that affects the periapical tissues surrounding teeth with infected root canal systems (Nair, 2006). Even though AP can be caused by a wide range of etiological factors, it is generally accepted that microorganisms within the root canal system are the primary cause of pulp necrosis and the consequent inflammatory response in the periapical region (Nair, 2006).

Radiographically, AP is characterized as a radiolucency around the roots of an affected tooth due to damaged periradicular tissues (Jakovljevic et al., 2021). AP is usually diagnosed during routine radiographic examination since it is often asymptomatic (Kruse et al., 2014). Hence, radiographic assessment is crucial in terms of both diagnosis and follow-up of the healing process after treatment (Bergenholtz et al., 2010). Periapical lesions are routinely monitored using intraoral periapical radiographs (IOPAR) (Lo Giudice et al., 2018; Metska et al., 2013; Ørstavik & Pitt Ford, 2008). However, periapical and panoramic radiographs have inherent limitations, including anatomical noise (Bender & Seltzer, 2003) and some degree of geometric distortion (Forsberg & Halse, 1994), which may hinder the accurate detection of periapical lesions within cancellous bone (Abella et al., 2014; Davies et al., 2016), particularly when the buccal cortical bone is thick (Lo Giudice et al., 2018). These limitations can largely be overcome through cone beam computed tomography (CBCT), which, despite providing a lower spatial resolution than periapical radiographs, provides a three-dimensional (3D) visualization of structures (Kruse et al., 2014).

Management of AP is determined by the presence of periapical pathosis and its change over time (Ng et al., 2011). An increase in the size of lesion after root canal treatment or retreatment indicates that other treatments such as apical surgery or intentional re-plantation are necessary to save the tooth. In contrast, a decrease in the size of the lesion or its complete disappearance is synonymous with healing (European Society of Endodontology, 2006). Periapical healing is

an essential process to restore tissue integrity (Holland et al., 2017), particularly in large periapical lesions that may cause cortical expansion, cortical plate erosion or inflammatory root resorption of the surrounding teeth (Sharma et al., 2018). It is worth mentioning that a range of therapeutic factors (e.g. type and quantity irrigant solution, type of intracanal dressing or root canal filling), patient's systemic condition and physiology (e.g. chronic diseases or age) can interfere with the periapical healing process and affect the prognosis of root canal treatment (Holland et al., 2017; Georgiou et al., 2020; Jakovljevic et al., 2020).

Clinicians do not expect all large periapical lesions to heal completely after root canal treatment, particularly when there are evident borders radiographically mimicking periapical bone cysts (Saini et al., 2023). However, it is not possible to differentiate clinically or radiographically whether the periapical lesion is a granuloma or a cyst (White et al., 1994). This information can only be acquired from an accurate histopathological diagnosis of the entire lesion and root apex (Ricucci et al., 2020). Although histological examination remains the *gold standard* for diagnosing the presence and severity of AP, the invasiveness of the procedure impedes its routine use (Kruse et al., 2014). Consequently, diagnosis of AP is carried out clinically and radiographically. Evaluation of a periapical lesion is recommended until it has healed or for at least 4 years post-treatment (European Society of Endodontology, 2006). Persistence of a lesion after 4 years indicates that root canal treatment is associated with a post-treatment disease, when additional treatment should be considered (European Society of Endodontology, 2006).

The main aim of the present retrospective study was to evaluate the healing of large periapical lesions and determine the minimum follow-up required after a nonsurgical root canal treatment or a nonsurgical retreatment. A secondary objective was to analyse the effects of initial volume of the lesion, age and gender of the patient, type of treatment (root canal treatment or retreatment) or type of root canal filling (gutta-percha or calcium silicate-based material) on the healing time.

MATERIALS AND METHODS

Ethics and reporting guidelines

The current study design was approved by the Research Ethics Committee (Santiago, de Compostela – Lugo (Galicia, Spain), approval No: 2021/508). The current study was reported according to Preferred Reporting items for Observational studies in Endodontics (PROBE) 2023 guidelines (Nagendrababu et al., 2023).

Sample size estimation

A random sample of 79 individuals was sufficient to estimate, with a confidence level of 95% and a precision of ± 10.7 percentage units, a population percentage that was predicted to be around 63%. An estimate of a 63% healing rate was made based on 24 months of data (Zhang et al., 2015). The calculations were made using the GRANMO sample size calculator. (<https://www.imim.es/ofertadeserveis/software-public/granmo/>).

Case selection criteria

In this retrospective study, images of IOPAR/CBCT and clinical data belonged to 79 patients from the Masters of Endodontics, Restorative and Aesthetic Dentistry (University of Santiago de Compostela, Spain) in collaboration with five private clinics (Endodontic practice, Spain). Participants were informed of the purpose of the study and provided written consent. Seventy-nine patients were selected by five operators who participated in this study. The inclusion criteria were that patients had an initial periapical lesion on IOPARs ranging in size from 10 to 15 mm at their greatest diameter (Calişkan, 2004; Saini et al., 2023). Root canal treatment or retreatment was performed between January 2013 and December 2020 with radiographic follow-ups every 6 months and CBCT every 1 year until healing or when further treatment was deemed necessary up to 48 months. The exclusion criteria were teeth with limited remaining tooth structure, cases of endodontic microsurgery, teeth extracted for nonendodontic reasons and teeth with signs or symptoms of post-treatment disease during the follow-up period of 48 months. Additionally, teeth were excluded if they had previous periodontal disease, underwent prior surgical endodontic treatment, or if the apex was not visible on any of the radiographs. Teeth were excluded from the analysis of 'periapical status following treatment' if details on the periapical status at the time of extraction were unavailable and an adequate pre and intraoperative dataset was not obtained for each tooth.

Preoperative radiological assessment and volumetric measurement

All radiographs were taken using 'as low as diagnostically acceptable' (ALADA) principle and standard imaging protocol. The IOPAR were exposed with an X-ray generator (VistaIntra DC, Durr Dental Médics Ibérica, Barcelona, España) and digital imaging plates (Soredex, Tuusula, Finland) under the following parameters: 65 kV, 7 mA and 0.12 s exposure time. IOPAR was taken with the paralleling technique using a film holder (Rinn XCP Ring® positioner, Dentsply, Constanz, Germany). The exposed imaging plates were introduced into the scanner (CS 7600; Carestream Dental LLC, Atlanta, Georgia) and were read using the CS Imaging version 8 software (Carestream Dental LLC). The IOPAR of each patient was assessed on a 23.8-inch flat screen monitor (HP Pavilion, Palo Alto, CA, USA) in a quiet, dimly lit room and the greatest diameter of periapical lesion was recorded in. Initial 2D measurements were made by two endodontists, the kappa value for the initial agreement was 0.75; cases in doubt were resolved by discussion. Adjustments in contrast or magnification of images during the observation were avoided to prevent subjective changes in the dimensions of lesion as they were captured under standard radiographic exposure conditions. Subsequently, a CBCT scan was performed with the Carestream CS9300 Select equipment (CS 9300, Carestream Dental LLC, Atlanta, Georgia, USA) following the manufacturer's instructions under standard exposure settings (84 kV and 5 mA) and patient position. The voxel size was 0.18 mm, with a field of view (FOV) of 5 × 5 cm and an exposure time of 20 s. The images were reconstructed with the CS 3D Imaging Software (Carestream Dental LLC) and exported using the DICOM format to a 3D planning software to perform the volumetric measurements (OsiriX Lite software, Pixmeo, Geneva, Switzerland; www.osirix-viewer.com).

Volumetric measurements were made in the axial plane to visualize the lesion in its maximum extension in the apicocoronal direction. A 'closed polygon' tool was used to delimit the border of the lesion whilst scrolling the slices from the beginning of the lesion (Figure 1a). The border of the lesion was demarcated in each slice (Figure 1b) to calculate the volume (Figure 1c). The volumetric measurements of the periapical lesions before treatment and during follow-ups were recorded on an Excel spreadsheet (Microsoft Excel 2016, Microsoft Corporation).

Assessment of medical records

The following patient-specific information was recorded: name, file number, the tooth involved, age, gender, type of

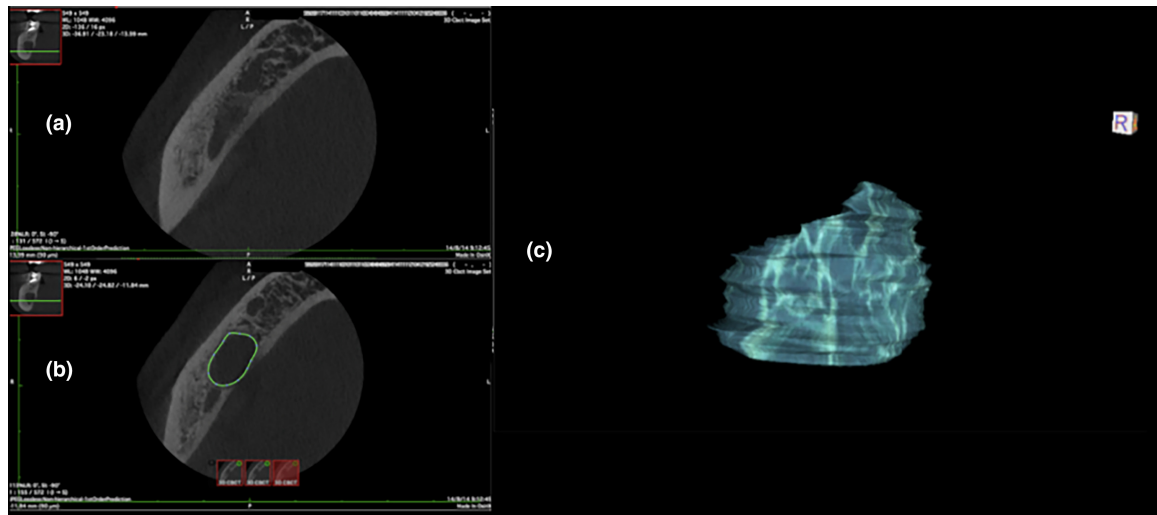


FIGURE 1 (a) Initial position before first volumetric measurement. (b) Delimitation of the lesion in the axial plane for volumetric measurement. (c) Calculation of the initial volume.

treatment (root canal treatment or retreatment) and filling material (gutta-percha or calcium silicate-based material).

Clinical procedures

The root canal treatment and retreatments were performed by five endodontists with more than 8 years of experience, who collected the preoperative, intraoperative and postoperative information following the same protocol.

The treatments were carried out under rubber dam isolation and using an operative microscope. The access opening was performed with Endo Access burs (Dentsply Tulsa Dental Specialties; Tulsa, Oklahoma, USA) and Endo-Z burs (Dentsply, Maillefer, Ballaigues, Switzerland). In primary endodontic infections, the patency of all root canals was verified with manual files K-Flexofile (Dentsply Maillefer, Ballaigues, Switzerland) K-File (Endogal, Sarria, Lugo, Spain). After an adequate glide-path was established, the rotary instrumentation systems, ProTaper Gold (Dentsply Maillefer, Ballaigues, Switzerland) or Endogal (Sarria, Lugo, Spain) were used. The nonsurgical retreatments were performed with ProTaper retreatment files (Dentsply Maillefer; Ballaigues, Switzerland) and Endogal files.

Mechanical instrumentation of canals was carried out with abundant and regular use of sodium hypochlorite at 5.25% (Dentaflux, Madrid, Spain) with ultrasonic activation. The treatment was carried out in two sessions with intracanal medication between visits (Endocalcium, Endogal, Sarria, Lugo, Spain).

Finally, the canal system was filled using the continuous wave technique and resin cements, AH Plus

sealer (Dentsply DeTrey GmbH, Konstanz, Germany) or Endoresin cement (Endogal, Sarria, Lugo, Spain). The calcium silicate-based materials, ProRoot MTA (Dentsply Maillefer, Ballaigues, Switzerland), Biodentine (Septodont, Saint-Maur-des-Fossés, France) and EVO MTA (Endogal, Sarria, Lugo, Spain), were also used in those canals where the apical constriction had a diameter of greater than 0.5 mm. The temporary coronal restoration between visits was performed with polytetrafluoroethylene (PTFE) tape (Diamond, India, ISO 9001:2000, 12 mm) and Grandioso Flow (GRAFL; VoCo, Cuxhaven, Germany) until the coronal restorations were placed.

Clinical evaluation and postoperative radiological evaluation

Patients were evaluated periodically at 6-month intervals for the presence or absence of signs and symptoms such as pain on palpation/percussion and swelling. At each follow-up visit, an IOPAR was taken under the same standard conditions and compared with the pre-treatment IOPAR for the greater diameter of the periapical lesion. Similarly, after every 12 months, in addition to the IOPAR, a CBCT was taken to compare the volume of the lesion. A confirmatory CBCT was performed during the specific 6 month's follow-up where no periapical lesion was observed on the IOPAR. The integrity of the final restoration was assessed during each visit.

Two blinded endodontists assessed the pre and postoperative IOPAR and CBCT images. By giving each image/volume a random number and arranging them in a random order, the observers were blinded on the treatment status of patients. To calibrate the examiners prior to the

study, they examined 10 volumes independently. After evaluation, a kappa value for agreement was calculated (weighted kappa values, $k=0.8$), when discrepancies occurred the observations were compared and discussed in order to reach an agreement. The treatment was considered a success when there was no periapical lesion on the CBCT images. Absence of periapical lesion was recorded when the reconstructed volume of the lesion in on the CBCT image was less than twice the width of the periodontal ligament (Low et al., 2008; Metska et al., 2013) and the volume was noted as zero. If the volume of the lesion had decreased or remained the same, follow-up visits were continued for up to 4 years. To determine the progress of healing comparisons were always made with the volume of the lesion calculated on the CBCT image of the previous follow-up. In the fourth year, if a tooth still had a periapical lesion, it was considered a failed treatment. It was also considered a failed treatment when the lesion size increased during the follow-ups and if an extraction was necessary due to fractures or periodontal defects with a poor prognosis. The healing of the lesion was dichotomized as completely healed or not healed based on the above protocol. The postoperative radiological evaluation is described in [Figure 2](#).

Statistical analysis

The statistical analysis was performed using SPSS software (v.20; IBM). The quantitative variables (age, volume and healing time) were described using position statistics (mean and median) and dispersion (range, interquartile range and standard deviation). The qualitative variables (gender, type of filling material and type of treatment) were described using absolute and relative frequencies.

The healed and unhealed cases were compared to determine any differential factors between the two groups. Pearson's Chi-square test was used for categorical variables. To choose the tests for comparison of quantitative variables, the normality and homoscedasticity of the variables were evaluated using Anderson–Darling and Fligner–Killen tests, respectively. Student's *t*-test was used when normality and homoscedasticity assumptions were met, Welch's *t*-test was used when there was heteroscedasticity and Wilcoxon–Mann–Whitney test was used when normality assumptions were violated.

The association of healing time with the rest of the variables included in the data set amongst the healed patients was evaluated through a univariate analysis (variable by variable). The Wilcoxon test was used to observe the association of categorical variables with healing time. In the association of time with quantitative variables, the Pearson correlation coefficient was measured.

Nonparametric (i.e. Turnbull's Estimator) and accelerated failure time models were adjusted for healing times obtained from 6-months intervals and using the *icenReg* package (Anderson-Bergman, 2017) of R 4.0 (R Core Team, 2021). Total healing time is defined as the interval between visits during the patient's recovery. Different distributions were tested for time until the one that the best fit with the data according to the Akaike Information Criterion (AIC) was found. For the selection of variables that were included in the model, the stepwise methodology of selection of covariates according to the AIC was used and all those that were not significant were eliminated from the model. The survival model coefficients were associated with the healing time with an exponential relationship.

The level of significance was established at $p < .05$.

RESULTS

Of the 180 screened patients, data from 79 patients were used of which 41 (52%) were men and 38 (48%) were women, whose mean age was 44 (SD=16.3) years old. In relation to the type of treatment, 47 (60%) cases were retreatment and 32 (40%) were primary root canal treatment. The process of inclusion and exclusion of cases for the purpose of participation eligibility in the current study and the case follow-up is described in [Figure 3](#).

Overall, 60 patients had complete healing of the periapical lesion with a mean healing time of 19 months ([Figure 4](#)). Complete healing of the periapical lesion did not occur in 19 patients ([Figure 5](#)); 14 of them underwent periapical surgery of the affected teeth because of the increase in lesion size during the follow-up period and five of them underwent extraction (two due to traumatic fractures and three due to periodontal defects). The clinical data and the volumetric measurements of each periapical lesion during its follow-up are presented in [Table 1](#).

The main statistically significant difference between patients with complete healing of the periapical lesion and those without was age (Student's test $t_{77} = -2.81$, $p < .01$). Patients with complete healing of the periapical lesion had a mean age of 41.2 years (SD=15.3) and unhealed ones of 52.8 years (SD=16.7). Furthermore, a first correlation analysis revealed an increase in healing time according to the initial volume of the periapical lesion in mm^3 ($r_{\text{Pearson}} = 0.40$, $p < .01$). Therefore, increased age and larger initial volume of the lesion were significant predictors for the healing of periapical lesions.

Subsequently, using a parametric survival model, the effect of the covariates on healing time was evaluated. The distribution chosen for the time was gamma by offering a better fit and minimizing the AIC, compared to the

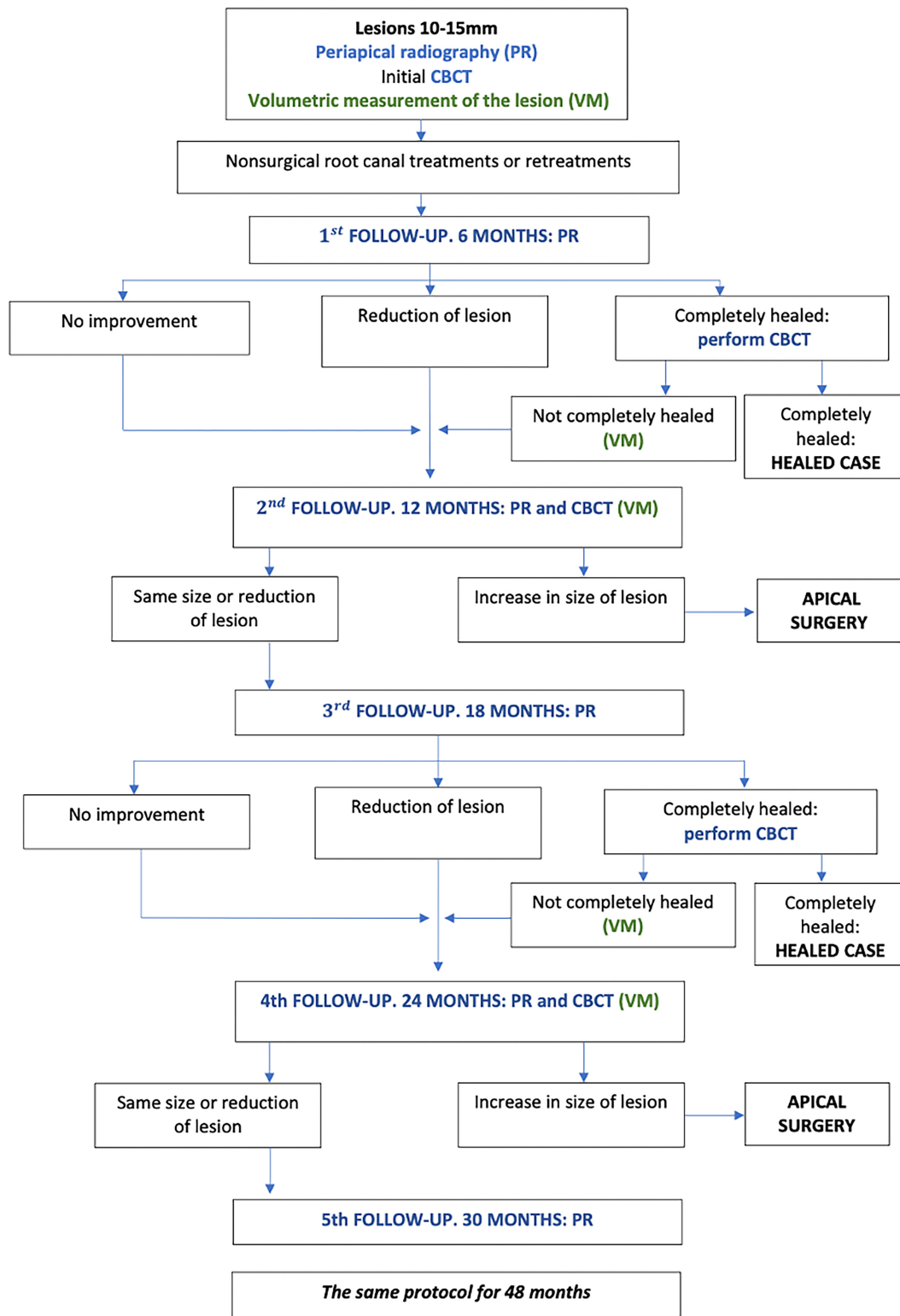


FIGURE 2 Flow chart of postoperative radiological evaluation.

exponential one (Figure 6). More than 60% of the patients displayed healing between months 12 and 18. Therefore, in this analysis, it was confirmed that older age and larger initial lesion size was associated with longer healing time ($p < .001$). Specifically, given the regression coefficients

for age ($\beta_{Age} = 0.048$, $e^{0.048} = 1.049$) and initial volume of the lesion ($\beta_{Vol} = 0.003$, $e^{0.003} = 1.003$), it is concluded that a 1-year increase in age increased the healing time by 4.9% and that an increase in 1 mm^3 in the initial volume of the lesion increased healing time by 0.3% whilst the other

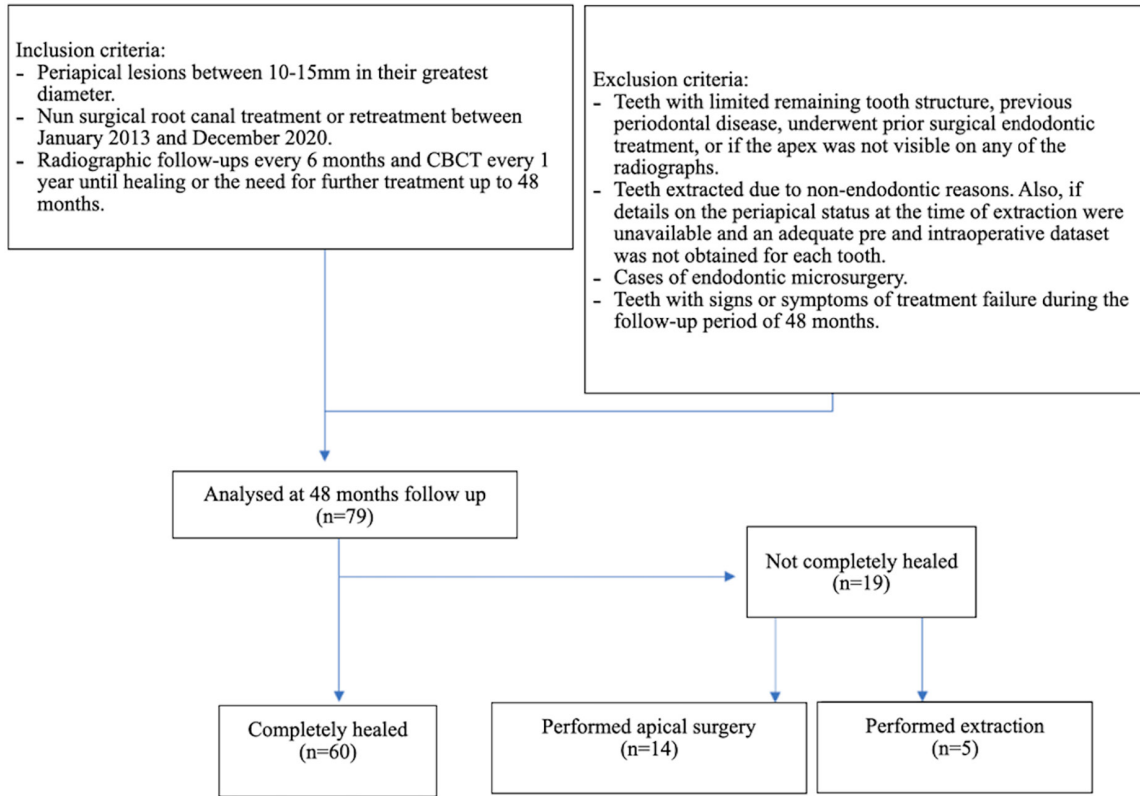


FIGURE 3 Flow chart of the study outline.

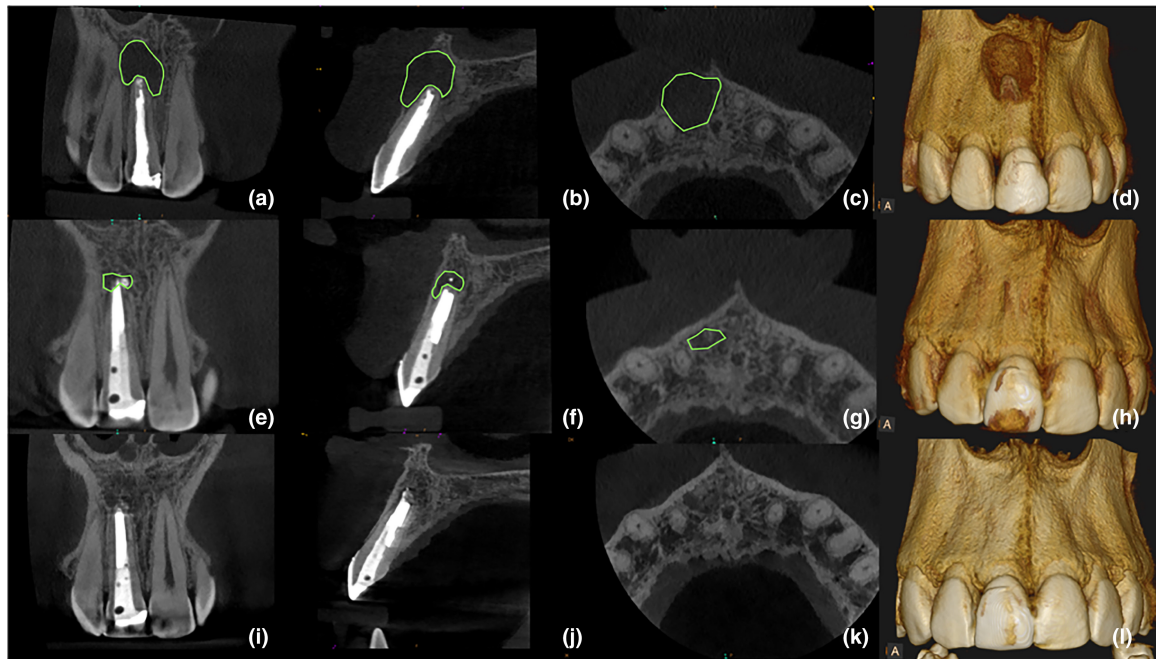


FIGURE 4 Multiplanar reconstructed CBCT images of a healed case at 24 months follow-up. Preoperative (a–d), 12 months follow-up (e–h) and 24 months follow-up (i–l).

variables remained constant (Table 2). The marginal effect of age and lesion size on healing time at its mean value can be seen graphically in Figures 7 and 8. The

final model with two covariates minimizes the AIC and showed an acceptable predictive performance ($R^2=0.43$). Gender, type of filling material, and type of treatment had

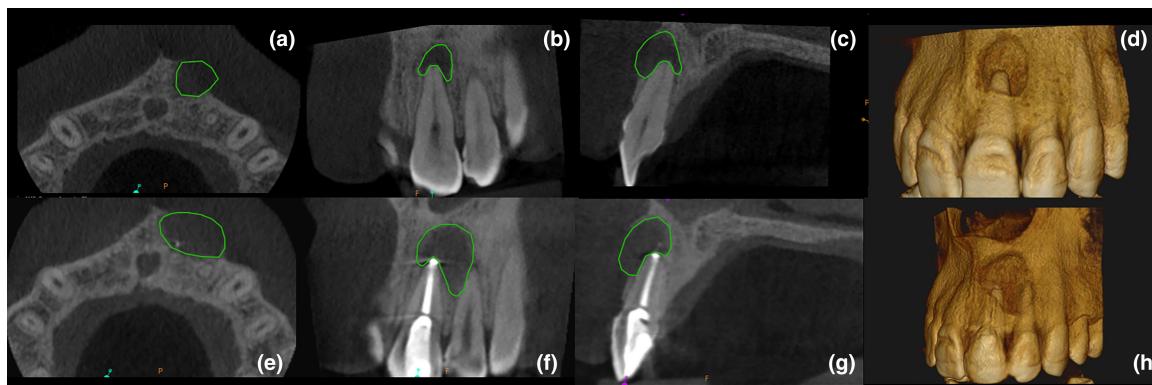


FIGURE 5 Multiplanar reconstructed CBCT images of an unhealed case at 12 months follow-up. Preoperative (a–d), 12 months follow-up (e–h).

TABLE 1 Descriptive analysis between healed and not healed patients, and total.

Variable	Healed (<i>N</i> = 60)	Not healed (<i>N</i> = 19)	Total (<i>N</i> = 79)	<i>p</i> -Value
Sex				
<i>N</i>	60	19	79	.55 (a)
Male	30 (50.0%)	11 (57.9%)	41 (51.9%)	
Female	30 (50.0%)	8 (42.1%)	38 (48.1%)	
Age (years)				
<i>N</i>	60	19	79	<.01 (b)
Mean (SD)	41.23 (15.29)	52.79 (16.68)	44.01 (16.30)	
Median (IQR)	38 (25.5)	56 (24.5)	40 (24.5)	
Treatment				
<i>N</i>	60	19	79	.36 (a)
RCT	26 (43.3%)	6 (31.6%)	32 (40.5%)	
NSR	34 (56.7%)	13 (68.4%)	47 (59.5%)	
Material				
<i>N</i>	60	19	79	.75 (a)
Calcium silicate-based material	8 (13.3%)	2 (10.5%)	10 (12.7%)	
Gutta-percha	52 (86.7%)	17 (89.5%)	69 (87.3%)	
Initial volume (mm ³)				
<i>N</i>	60	19	79	.76 (c)
Mean (SD)	222.49 (225.75)	215.53 (276.43)	220.81 (237.05)	
Median (IQR)	113 (270.4)	102.9 (130.65)	108.3 (226.4)	

Note: Tests used: (a) chi-square; (b) Student's *t*-test; (c) Wilcoxon–Mann–Whitney test. SD (standard deviation).

no effect on healing ($p > .05$) in the complete model and were excluded from the final model after applying a variable selection step.

DISCUSSION

In the current study, the post-treatment evaluation of 79 patients with a periapical lesion ranging in size from 10 to 15 mm at their greatest diameter (Calışkan, 2004; Saini et al., 2023) was evaluated retrospectively. Monitoring

each periapical lesion with CBCT imaging allowed volumetric measurements to have an objective and quantifiable view of the process. The main objective to follow-up a periapical lesion after primary root canal treatment or nonsurgical retreatment is to observe the healing process and rule out its persistence (European Society of Endodontology, 2006). The aim of this study was to evaluate the successful healing of large periapical lesions and to determine the minimum required follow-up time. Furthermore, the purpose was also to analyse the possible factors that could influence this healing process.

A standard protocol was followed for all cases by both the faculty of university clinics and endodontist of private clinics, where a medication with calcium hydroxide (Best et al., 2021) is placed for a month, to check resolution of sinus tract, fistulous process, or the abscess (if there is one) and the disappearance of pain. These factors are favourable clinical signs of effective root canal disinfection (Ordinola-Zapata et al., 2022). The outcome of the treatment was that 60% healed between 12 and 18 months. The study by Metska et al. (2013) revealed, after evaluating the volumetric changes, a significant reduction in the size of periapical lesions 1 year after root canal retreatment in more than 50% of the teeth. Zhang et al. (2015) observed that the rate of reduction of periapical lesions after endodontic treatment was higher during the first-year of follow-up. They stated that

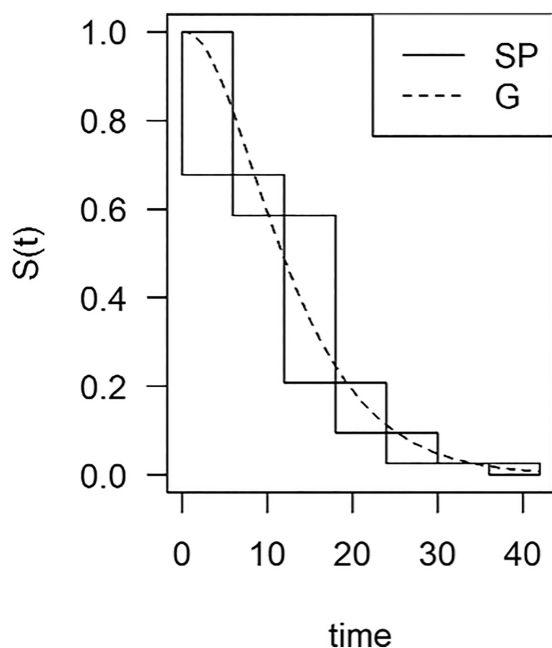


FIGURE 6 Baseline survival graph of time to complete healing of the lesion ($S(t)$) over time (months). Continuous lines represent the Turnbull's nonparametric estimator for the survival (SP) and dashed line represents the parametric model with a Gamma distribution (G).

TABLE 2 Coefficients of the adjusted parametric survival model after the variable selection step, with its standard error, the z -test statistic and the associated p -value.

	Coefficient	Exponential (Coefficient) ^a	SE	z -Value	p -Value ^b
Age (years)	0.05	1.05	0.01	3.19	.002**
Initial volume (mm ³)	0.003	1	<0.01	3.25	.001**
Log (shape)	0.65	1.92	0.24	2.77	.006**
Log (scale)	2.26	9.59	0.26	8.63	<.001***

Note: ** = $p \leq .01$; *** = $p < .001$.

^aExponential of the regression coefficient.

^bSignificance.

the greatest decrease occurred in the time immediately after the treatment was performed (Zhang et al., 2015). Weissman et al., 2021 evaluated 384 teeth postoperatively for a follow-up period of 48 months using 2D radiographic images and concluded that the healing process of periapical lesions at 12 months provide a good indication of the long-term result of the treatment. However, follow-up with 2D radiography alone, as is well known, has inherent limitations, including anatomical noise (Bender & Seltzer, 2003) and some degree of geometric distortion (Forsberg & Halse, 1994), which may hinder the accurate detection of periapical lesions within cancellous bone (Abella et al., 2014; Davies et al., 2016), particularly, when the buccal cortical bone is thick (Lo Giudice et al., 2018). These limitations may mask an increase in the size of the lesion and delay further appropriate treatment. Objective monitoring of these lesions on the basis of low radiation is also crucial as over-radiation could compromise the overall health of the patient.

Healing of a periapical lesion of endodontic origin is a dynamic process and requires sufficient time to assess its progression and completion (Zhang et al., 2015). The absence of pain, inflammation, loss of function and radiographic evidence of normal periodontal tissues indicate a favourable treatment outcome. The root canal treatment is considered uncertain when radiographically the lesion has remained the same size or has decreased in size, but not completely disappeared. If a lesion persists after 4 years, the root canal treatment is usually considered to be associated with post-treatment disease (European Society of Endodontology, 2006). Exceptionally, an extensive radiolucent lesion may heal but leave an irregularly shaped demineralized area visible locally. This defect may be the formation of scar tissue rather than a sign of persistent apical periodontitis and the tooth should be further evaluated (European Society of Endodontology, 2006).

Furthermore, differential diagnosis of radiographically identified periapical lesion is important to consider as not every periapical lesion is a dental granuloma that will heal. Bhaskar (1966) studied 2308 cases with radiolucency in the apical areas of the teeth. Nine different types

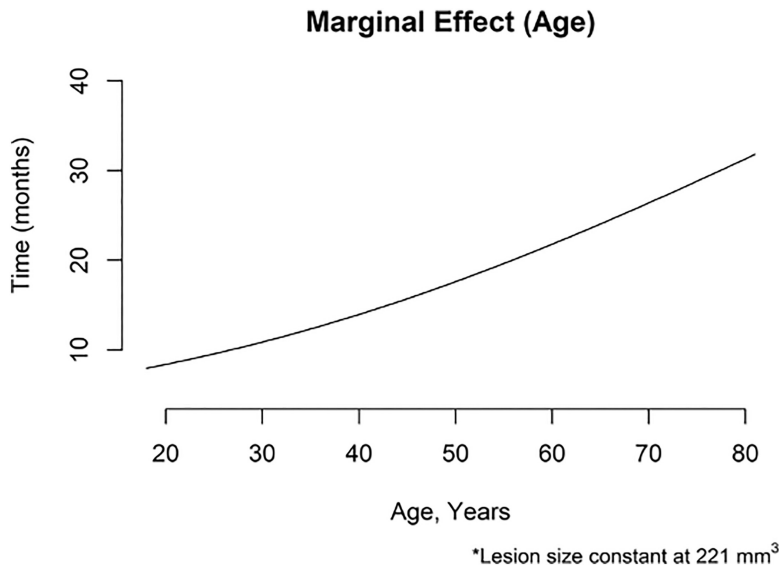


FIGURE 7 The marginal effect of age when lesion size remains constant.

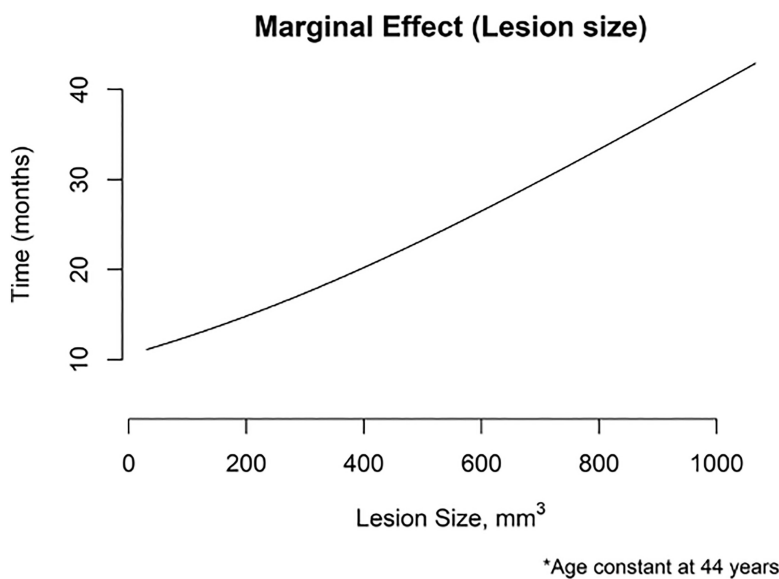


FIGURE 8 The marginal effect of lesion size when age remains constant.

of lesions were observed microscopically. There were 48% dental granuloma, 42% radicular cyst, 3.7% residual cyst, 2.5% apical scar, 1.2% cementoma, 1.1% dental abscess, 1% foreign-body reaction, 0.4% cholesteatoma and 0.1% giant-cell lesion. According to the relationship of the cyst cavity with the root canal via the apical foramen, an apical cyst has been classified as a ‘true’ or ‘bay’ (also ‘pocket’) cyst. Bay cysts communicate directly with the root canal through the apical foramen. In contrast, the true cyst has an independent cavity, without connection to the root canal (Simon, 1980). All periapical lesions of endodontic origin, including bay cysts, are primarily caused by bacteria and microorganisms inside the root canal system (Nair, 2006). Therefore, these lesions are expected to heal when the source of infection is eliminated (Lin et al., 2007). There is no consensus in the literature about whether true cysts are self-sustainable or not (Ricucci et al., 2020), but the initial

treatment protocol should begin with root canal treatment to remove any infectious agents that may be present inside the root canals. Surgery should only be performed if there is no healing after orthograde treatment (Lin et al., 2009). A reason why a periapical lesion persists over time despite removing the original microbiological stimulation within the root canal system could be attributed to the various types of lesions (Nair, 2004).

It is to remember that there are cystic lesions of non-endodontic origin and neoplastic lesions that can contribute to an inaccurate diagnosis and an ineffective treatment plan (Sirotheau Corrêa Pontes et al., 2014). Ortega et al. (2007) emphasize the importance of following up patients with periapical radiolucencies who have received root canal treatment. The study concluded that keratocystic odontogenic tumour were the most frequent nonendodontic lesion. Kontogiannis et al., 2015 advocated

that lesions should be studied histopathologically, especially large lesions, because they could be odontogenic tumours, such as ameloblastoma or malignant lesions. Evangelista et al. (2022) emphasized that endodontists should be aware of unsuccessful treatments, rapid growth rates or a delayed response to treatment. They concluded that complementary examinations, such as biopsy and computed tomography, would allow early diagnosis of malignant tumours.

In the analysis of database, there were mainly two factors that affected the healing process. On the one hand, the age of the patient was the only statistically significant difference between healed and unhealed patients. A 1-year increase in age in patients increased the healing time of the periapical lesions by 4.9%. The second factor that was associated with a longer healing time was the initial size of the lesion. An increase in 1 mm^3 in the initial volume of a periapical lesions increased the healing time by 0.3%. Liu et al. (2021) analysed the prognostic factors of root canal treatment and nonsurgical retreatment for teeth with apical periodontitis. They observed that a statistically significant preoperative prognostic factor in the successful healing rate was the patient's age ($p < .05$). Younger patients had a more favourable outcome (Liu et al., 2021). Other authors disagree with this finding, for example, Saini et al., 2023 concluded that age was not a prognostic factor for the healing process. However, the mean age of their sample was 26.6 years ranging from 18 to 55 years old, thus, it is not comparable to the mean age of the present study (44 years, ranging from 18 to 81 years old). Furthermore, in their study a CBCT follow-up of the lesion was only performed at 24 months (Saini et al., 2023). An objective follow-up of the evolution of the lesion over time was not carried out, it was only done at a single point in time. As already mentioned, the healing process of a periapical lesion is dynamic and more time is needed to determine whether a result is favourable or not (European Society of Endodontology, 2006; Zhang et al., 2015). On the other hand, in this study, gender, type of treatment and filling material was not associated with any statistically significant differences in the healing process.

It is important to follow-up periapical lesions through a small field of view CBCT. Schloss et al. (2017) published a study with 51 teeth comparing the healing of apical lesions after endodontic surgery using periapical radiographs and CBCT images. The variation in the outcome of healed lesions when viewed in 2D and 3D images was significantly different. They concluded that 3D images help to accurately classify states of incomplete or uncertain healing that had led to a doubtful diagnosis from 2D images (Schloss et al., 2017). Also, in the study carried out by Davies et al. (2016) it was reported that diagnosis by

CBCT revealed a significantly lower number of favourable results than periapical radiographs in the nonsurgical re-treatment of root canals.

The effective dose in a $5 \times 5\text{ cm}$ field of view varies based on type of scanners and the region of the jaw being scanned (Patel et al., 2019; Special Committee to Revise the Joint AAE/AAOMR Position Statement on use of CBCT in Endodontics, 2015). In general, the smallest FOVs have median effective doses under $100\text{ }\mu\text{Sv}$ (Mah et al., 2021). A study by Pauwels et al., 2012 showed that a small-field CBCT has a radiation dose of between 0.019 and 0.044 mSv. According to the Spanish Society for Radiological Protection, an IOPAR has a radiation dose of 0,0035 mSv. The ALARA (As Low As Reasonably Achievable) principle advocates that all radiation exposures should be kept as low as reasonably possible. The dose limits established in Spanish legislation guarantee that people are not exposed to an unacceptable level of risk and consider that the maximum effective dose should be 100 mSv in a period of five official years, not exceeding 50 mSv in 1 year; for members of the public is 1 mSv per year (EURATOM) (<https://www.boe.es/eli/es/rd/2022/12/20/1029>). If a follow-up CBCT and an IOPAR was performed every 6 months during the first year after treatment, patients would be subjected to an effective radiation dose of at most 0.095 mSv in 1 year, a figure much lower than the maximum dose allowed. Based on the results of this study, 6-month follow-up appointment was beneficial to verify the healing process. In this study, 8.9% of the cases revealed that the lesions healed completely in the first 6 months. However, the authors did not consider this to be sufficient time to make an accurate decision about an additional treatment plan if the lesion did not show clear signs of healing within this time. To confirm objectively that the periapical lesion was completely healed, a CBCT image was obtained 2 years after the treatment (Figure 4) even with apparently total healing on IOPARs. The possible benefit for the patient in subjecting them to such confirmatory investigation is to determine the fate of large lesion, whereas for clinician the benefit is to confirm whether the bone has formed completely, a scar has remained, or it has increased in size, where surgery would be indicated.

Currently, there is no protocol that indicates how and in what way large periapical lesions should be followed up after root canal treatments. The fact of carrying out a quantitative control of the size of lesions through volumetric measurements allows us to make an objective evaluation of the changes over time. In this study, volumetric measurements were carried out by an operator manually with a specific software program. A CBCT was performed in all patients at 12 months and the volumes of the lesions were calculated and compared to the initial

ones. In 14 cases the volume of the lesion increased during the follow-up and apical surgery was necessary. In the rest of the cases in which the lesion remained the same or decreased in size, the follow-up appointment was scheduled (European Society of Endodontology, 2006). A confirmatory CBCT was performed at the 6th month follow-up to rule out the ambiguity in radiographs regarding the healing of periapical lesions. As CBCT equipments have become more advanced with integrated volumetric comparison module incorporated within the software, monitoring the progression or regression of periapical lesion becomes an easy task (Economopoulos et al., 2012).

Since the patients are investigated for healing of periapical lesion at specific points in timeline corresponding to the recall appointment, the healing time determined in this study may not be close to the exact time period of healing which is a potential limitation of this study. Although the protocol for monitoring patients with periapical lesions by subjecting them to repeated CBCTs was approved by the ethics committee for research purposes, frequent exposure of patients to radiation is a primary ethical concern. Hence, in clinical practice, we must follow the ALARA principle and remember that routine follow-up procedures do not include CBCT scans as per the European Society of Endodontology guidelines (European Society of Endodontology, 2006).

CONCLUSION

Clinicians must take into account the two factors that may influence the success of the treatment associated with teeth with large periapical lesions: the age of the patient and the initial size of the lesion. The healing time of bone in patients with the same lesion size increased for older patients by 4.9% for each year difference in age. On the other hand, in patients of the same age, the healing time increased by 0.3% for each mm³ increase in the size of the lesion.

AUTHOR CONTRIBUTIONS

All the authors made substantial contributions to the manuscript. All the authors have read and approved the final version of the manuscript.

FUNDING INFORMATION

No source of financial support.

CONFLICT OF INTEREST STATEMENT

The authors have stated explicitly that there are no conflicts of interest in connection with this article.

DATA AVAILABILITY STATEMENT

The data that support the findings of this study are available from the corresponding author upon reasonable request.

ETHICAL APPROVAL

Approved by the Research Ethics Committee of Santiago de Compostela – Lugo (Galicia, Spain) (Approval No: 2021/508; dated 23/03/2022).

PATIENT CONSENT STATEMENT


Participants were informed of the purpose of the study and provided written consent.


ORCID


Carolina Mosquera-Barreiro  <https://orcid.org/0000-0002-2032-4681>

Manuel Ruiz-Piñón  <https://orcid.org/0000-0002-9110-3173>

Francesc Abella Sans  <https://orcid.org/0000-0002-3500-3039>

Venkateshbabu Nagendrababu  <https://orcid.org/0000-0003-3783-3156>

Thilla Sekar Vinothkumar  <https://orcid.org/0000-0001-9798-3872>

Jenifer Martín-González  <https://orcid.org/0000-0001-9282-133X>

Benjamín Martín-Biedma  <https://orcid.org/0000-0002-4297-4220>

Pablo Castelo-Baz  <https://orcid.org/0000-0003-3031-5532>

REFERENCES

- Abella, F., Patel, S., Durán-Sindreu, F., Mercadé, M., Bueno, R. & Roig, M. (2014) An evaluation of the periapical status of teeth with necrotic pulps using periapical radiography and cone-beam computed tomography. *International Endodontic Journal*, 47, 387–396.
- Anderson-Bergman, C. (2017) IcenReg: regression models for interval censored data in R. *Journal of Statistical Software*, 81, 1–23.
- Bender, I.B. & Seltzer, S. (2003) Roentgenographic and direct observation of experimental lesions in bone: II. 1961. *Journal of Endodontics*, 29, 707–712.
- Bergenholtz, G., Hørsted-Bindslev, P. & Reit, C. (2010) *Textbook of endodontology*, 2nd edition. Oxford, UK: Blackwell Publishing Ltd.
- Best, S., Ammons, C.L., Karunanayake, G.A., Saemundsson, S.R. & Tawil, P.Z. (2021) Outcome assessment of teeth with necrotic pulps and apical periodontitis treated with long-term calcium hydroxide. *Journal of Endodontics*, 47, 11–18.
- Bhaskar, S.N. (1966) Oral surgery—oral pathology conference No. 17, Walter Reed Army Medical Center. Periapical lesions—types, incidence, and clinical features. *Oral Surgery, Oral Medical and Oral Pathology*, 21, 657–671.

- Calışkan, M.K. (2004) Prognosis of large cyst-like periapical lesions following nonsurgical root canal treatment: a clinical review. *International Endodontic Journal*, 6, 408–416.
- Davies, A., Patel, S., Foschi, F., Andiappan, M., Mitchell, P.J. & Mannocci, F. (2016) The detection of periapical pathoses using digital periapical radiography and cone beam computed tomography in endodontically retreated teeth—part 2: a 1 year post-treatment follow-up. *International Endodontic Journal*, 49, 623–635.
- Economopoulos, T.L., Asvestas, P.A., Matsopoulos, G.K., Molnár, B. & Windisch, P. (2012) Volumetric difference evaluation of registered three-dimensional pre-operative and post-operative CT dental data. *Dentomaxillofacial Radiology*, 41, 328–339.
- European Society of Endodontology. (2006) Quality guidelines for endodontic treatment: consensus report of the European Society of Endodontology. *International Endodontic Journal*, 39, 921–930.
- Evangelista, K., de Faria, V.K., Teodoro, A.B., Cavalcanti, M.G.P., de Mendonça, E.F., Watanabe, S. et al. (2022) Malignant tumours mimicking periapical lesions: a report of three cases and literature review. *Australian Endodontic Journal*, 48, 515–521.
- Forsberg, J. & Halse, A. (1994) Radiographic simulation of a periapical lesion comparing the paralleling and the bisecting-angle techniques. *International Endodontic Journal*, 27, 133–138.
- Georgiou, A.C., Crielaard, W., Armenis, I., de Vries, R. & van der Waal, S.V. (2019) Apical periodontitis is associated with elevated concentrations of inflammatory mediators in peripheral blood: a systematic review and meta-analysis. *Journal of Endodontics*, 45, 1279–1295.e3.
- Holland, R., Filho, G.J.E., Cintra, L.T.A., Queiroz, Í.O.A. & Estrela, C. (2017) Factors affecting the periapical healing process of endodontically treated teeth. *Journal of Applied Oral Science*, 25, 465–476.
- Jakovljevic, A., Duncan, H.F., Nagendrababu, V., Jacimovic, J., Milasin, J. & Dummer, P. (2020) Association between cardiovascular diseases and apical periodontitis: an umbrella review. *International Endodontic Journal*, 10, 1374–1386.
- Jakovljevic, A., Sljivancanin Jakovljevic, T., Duncan, H.F., Nagendrababu, V., Jacimovic, J., Aminoshariae, A. et al. (2021) The association between apical periodontitis and adverse pregnancy outcomes: a systematic review. *International Endodontic Journal*, 9, 1527–1537.
- Kontogiannis, T.G., Tosios, K.I., Kerezoudis, N.P., Krithinakis, S., Christopoulos, P. & Sklavounou, A. (2015) Periapical lesions are not always a sequelae of pulpal necrosis: a retrospective study of 1521 biopsies. *International Endodontic Journal*, 48, 68–73.
- Kruse, C., Spin-Neto, R., Wenzel, A. & Kirkevang, L. (2014) Cone beam computed tomography and periapical lesions: a systematic review analysing studies on diagnostic efficacy by a hierarchical model. *International Endodontic Journal*, 48, 815–828.
- Lin, L.M., Huang, G.T.-J. & Rosenberg, P.A. (2007) Proliferation of epithelial cell rests, formation of apical cysts, and regression of apical cysts after periapical wound healing. *Journal of Endodontics*, 33, 908–916.
- Lin, L.M., Ricucci, D., Lin, J. & Rosenberg, P.A. (2009) Nonsurgical root canal therapy of large cyst-like inflammatory periapical lesions and inflammatory apical cysts. *Journal of Endodontics*, 35(5), 607–615.
- Liu, S.Q., Chen, X., Wang, X.X., Liu, W., Zhou, X. & Wang, X. (2021) Outcomes and prognostic factors of apical periodontitis by root canal treatment and endodontic microsurgery—a retrospective cohort study. *Annals of Palliative Medicine*, 10, 5027–5045.
- Lo Giudice, R., Nicita, F., Puleio, F., Alibrandi, A., Cervino, G., Lizio, A.S. et al. (2018) Accuracy of periapical radiography and CBCT in endodontic evaluation. *International Journal of Dentistry*, 2018, 1–7.
- Low, K.M., Dula, K., Bürgin, W. & von Arx, T. (2008) Comparison of periapical radiography and limited cone-beam tomography in posterior maxillary teeth referred for apical surgery. *Journal of Endodontics*, 34, 557–562.
- Mah, E., Ritenour, E.R. & Yao, H. (2021) A review of dental cone-beam CT dose conversion coefficients. *Dentomaxillofacial Radiology*, 3, 200–225.
- Metska, M., Parsa, A., Adriana Aartman, I., Wesseling, P. & Ozok, A. (2013) Volumetric changes in apical Radiolucencies of endodontically treated teeth assessed by cone-beam computed tomography 1 year after orthograde retreatment. *Journal of Endodontics*, 39, 1504–1509.
- Nagendrababu, V., Duncan, H.F., Fouad, A.F., Kirkevang, L.L., Parashos, P., Pigg, M. et al. (2023) PROBE 2023 guidelines for reporting observational studies in endodontics: a consensus-based development study. *International Endodontic Journal*, 56, 308–317.
- Nair, P.N. (2004) Pathogenesis of apical periodontitis and the causes of endodontic failures. *Critical Reviews in Oral Biology and Medicine*, 15, 348–381.
- Nair, P.N. (2006) On the causes of persistent apical periodontitis: a review. *International Endodontic Journal*, 39, 249–281.
- Ng, Y.L., Mann, V. & Gulabivala, K. (2011) A prospective study of the factors affecting outcomes of nonsurgical root canal treatment: part 1: periapical health. *International Endodontic Journal*, 44, 583–609.
- Ordinola-Zapata, R., Noblett, W.C., Perez-Ron, A., Ye, Z. & Vera, J. (2022) Present status and future directions of intracanal medicaments. *International Endodontic Journal*, 55, 613–636.
- Ørstavik, D. & Pitt Ford, T. (2008) *Essential endodontology: prevention and treatment of apical periodontitis*, 2nd edition. Oxford, UK: Blackwell Munksgaard Ltd.
- Ortega, A., Fariña, V., Gallardo, A., Espinoza, I. & Acosta, S. (2007) Nonendodontic periapical lesions: a retrospective study in Chile. *International Endodontic Journal*, 40, 86–90.
- Patel, S., Brown, J., Semper, M., Abella, F. & Mannocci, F. (2019) European Society of Endodontology position statement: use of cone beam computed tomography in endodontics: European Society of Endodontology (ESE) developed by. *International Endodontic Journal*, 12, 1675–1678.
- Pauwels, R., Beinsberger, J., Collaert, B., Theodorakou, C., Rogers, J., Walker, A. et al. (2012) Effective dose range for dental cone beam computed tomography scanners. *European Journal of Radiology*, 81, 267–271.
- R Core Team. (2021) *R: a language and environment for statistical computing*. Vienna, Austria: R Foundation for Statistical Computing. <https://www.R-project.org/>
- Ricucci, D., Rôças, I.N., Hernández, S. & Siqueira, J.F., Jr. (2020) "true" versus "bay" apical cysts: clinical, radiographic, histopathologic, and Histobacteriologic features. *Journal of Endodontics*, 46, 1217–1227.

- Saini, A., Nangia, D., Sharma, S., Kumar, V., Chawla, A., Logani, A. et al. (2023) Outcome and associated predictors for nonsurgical management of large cyst-like periapical lesions: a CBCT-based prospective cohort study. *International Endodontic Journal*, 56, 146–163.
- Schloss, T., Sonntag, D., Kohli, M. & Setzer, F. (2017) A comparison of 2- and 3-dimensional healing assessment after endodontic surgery using cone-beam computed tomographic volumes or periapical radiographs. *Journal of Endodontics*, 43, 1072–1079.
- Sharma, S., Sharma, V., Passi, D., Srivastava, D., Grover, S. & Dutta, S.R. (2018) Large periapical or cystic lesions in association with roots having open apices managed nonsurgically using 1-step apexification based on platelet-rich fibrin matrix and biodentine apical barrier: a case series. *Journal of Endodontics*, 44, 179–185.
- Simon, J.H. (1980) Incidence of periapical cysts in relation to the root canal. *Journal of Endodontics*, 6, 845–848.
- Sirotheau Corrêa Pontes, F., Paiva Fonseca, F., Souza de Jesus, A., Garcia Alves, A.C., Marques Araújo, L., Silva do Nascimento, L. et al. (2014) Nonendodontic lesions misdiagnosed as apical periodontitis lesions: series of case reports and review of literature. *Journal of Endodontics*, 40, 16–27.
- Special Committee to Revise the Joint AAE/AAOMR Position Statement on use of CBCT in Endodontics. (2015) AAE and AAOMR joint position statement: use of cone beam computed tomography in endodontics 2015 update. *Oral Surgery, Oral Medical, Oral Pathology and Oral Radiology*, 4, 508–512.
- Weissman, A., Wigler, R., Blau-Venezia, N., Goldberger, T. & Kfir, A. (2021) Healing after surgical retreatment at four time points: a retrospective study. *International Endodontic Journal*, 55, 145–151.
- White, S.C., Sapp, J.P., Seto, B.G. & Mankovich, N.J. (1994) Absence of radiometric differentiation between periapical cysts and granulomas. *Oral Surgery, Oral Medical and Oral Pathology*, 78, 650–654.
- Zhang, M.M., Liang, Y.H., Gao, X.J., Jiang, L., van der Sluis, L. & Wu, M.K. (2015) Management of Apical Periodontitis: healing of post-treatment periapical lesions present 1 year after endodontic treatment. *Journal of Endodontics*, 41, 1020–1025.

How to cite this article: Mosquera-Barreiro, C., Ruíz-Piñón, M., Sans, F.A., Nagendrababu, V., Vinothkumar, T.S., Martín-González, J. et al. (2024) Predictors of periapical bone healing associated with teeth having large periapical lesions following nonsurgical root canal treatment or retreatment: A cone beam computed tomography-based retrospective study. *International Endodontic Journal*, 57, 23–36. Available from: <https://doi.org/10.1111/iej.13993>