

# Wear in Two Cases of Ceramic on Ceramic Total Hip Arthroplasty After 30 Years Follow Up



Torres A<sup>\*1</sup>, Blanco A<sup>2</sup>, Coscujuela A<sup>3</sup>, Fernández Fairén M<sup>4</sup>, Sevilla P<sup>5</sup> and Gil FJ<sup>5,6</sup>

<sup>1</sup>Hospital Universitario Santa Lucía Calle Mezquita, Murcia, Spain

<sup>2</sup>Complejo Hospitalario General Yagüe-Divino Valles, Burgos, Spain

<sup>3</sup>Hospital de Bellvitge., Hospitalet de Llobregat, Spain

<sup>4</sup>Instituto de Cirugía Ortopédica y Traumatología de Barcelona. Diputación, Spain

<sup>5</sup>Biomechanics, Technical University of Catalonia, Spain

<sup>6</sup>School of Dentistry, Universitat Internacional de Catalunya, Spain

**Received:** January 24, 2018; **Published:** February 02, 2018

**\*Corresponding author:** Torres A, Hospital Universitario Santa Lucía. Calle Mezquita, s/n, 30202 Cartagena, Murcia, Spain, Email: anatpz@gmail.com

## Abstract

**Background:** Ceramic-on-ceramic (CoC) bearings have been in use in total hip replacement (THR) for more than 40 years, with excellent long-term survivorship but concerns over the ceramic-on-ceramic bearings wear persist. There are few studies where they analysed the ceramic-on-ceramic implants retrieved. We wanted to investigate the wear patterns and the surface properties of the CoC first generation THR implants removed.

**Case description:** We have analysed two cases of ceramic head on ceramic liner of Autophor primary THA implanted in active patients and retrieved for aseptic loosening after 34 and 31 years of well function. The sphericity, surface roughness and microtopography was assessed by a profilometer and a white light interferometer. Scanning electron microscopy of the implant-retrieved surfaces was also performed.

**Clinical relevance:** There is not a published study where retrieved implants of first generation CoC THR after more than 30 years of being implant were analysed. With the results obtained in our study, we have seen that the wear rate of ceramic-on-ceramic THA bearings, even those of the first generation, is low enough to allow a prolonged durability of the implants and offers a long-term survival of the arthroplasty.

## Introduction

Total hip replacement is one of the most successful surgical procedures. Ceramic-on-ceramic (CoC) bearings for total hip replacement (THR) were developed in the early 1970s. The earliest designs failed of inadequate fixation and high fracture rates [1,2]. Outstanding tribological properties of ceramic-ceramic bearings made them an important election as an ideal implant for younger patients undergoing THR [3-5]. Ceramic-on-ceramic bearings have shown the smallest wear volume in in vitro and in vivo studies [6,7]. The Mittelmeier Autophor™ cementless ceramic arthroplasty (Smith and Nephew, Memphis, TN) with ceramic-on-ceramic bearings of BioloX alumina (Feldmühle, Plochingen, Germany) was developed in 1974 and widely used around the 1980s. The Mittelmeier Autophor™ reduced the fracture rate but not the loosening [1,3,8-10].

The survival rate of this prosthesis was 98% after 17 years and the cause of their surgical revisions was the loosening of the

implants [5]. Newer ceramic materials (BioloX Delta; CeramTec AG, Plochingen, Germany) [11] have been modified to reduce the risk of wear rate compared to alumina and BioloX or BioloX Forte. Modern implants of CoC THR have shown an excellent survivorship up to 97% at 10 years [10]. Long-term retrieval analyses of CoC THR show higher wear rates [12-15] than the ones obtained in vitro with hip simulators [16-19]. Those long-term retrieval analyses of CoC THR published studies [12-14] were made with implants removed after less than 20 years of being implanted. There is not a published study where retrieved implants of first generation CoC THR after more than 30 years of being implant were analysed.

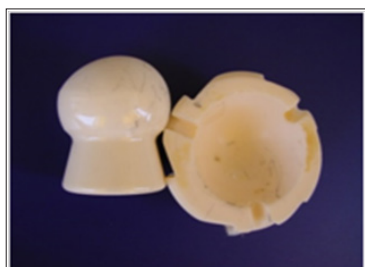## Material and Methods

We have analysed two cases of ceramic head on ceramic liner of Mittelmeier Autophor CoC THRs implanted in the 1980s through a posterior approach in active patients and retrieved after 34 and 31 years of well function. Bearings were made from an aluminum

oxide ceramic with content of 99.7% Al<sub>2</sub>O<sub>3</sub>, a maximum grain size of 4µm, a mean grain size of 4.2µm and a density of 3.94 g/cm<sup>3</sup>. The prostheses were from 1 men (77 years) and 1 women (68 years) at the implant retrieval moment. The reasons for hip arthroplasty were primary osteoarthritis secondary to developmental dysplasia in both cases. The indication for revision surgery was aseptic loosening. The head of the clinical case 1 was a first-generation mushroom-like head with a diameter of 38 mm. The head of the clinical case 2 was a neckless ceramic ball with 32mm of diameter. The retrieved implants were analysed visually to determine the obvious areas of wear. The sphericity, surface roughness and microtopography of the implants retrieved was assessed by a profilometer and a white light interferometer Veeco. A scanning electron microscopy of the surfaces was also performed. The samples were examined with an Environmental Scanning Electron Microscopy, Electroscan 2020, including a thermoelectric cooling stage which allowed ± 20°C variations in temperature compared to room temperature.

The gas used was water vapour at 5-10 Torr and the temperature was between 5 and 7°C in order to keep the samples hydrated for as long as possible. White light interferometry (Wyko NT1100 Optical Interferometer, Veeco Instruments, USA), in its vertical scanning interferometry mode, was used to produce, evaluate and quantify the topography. The interferometric technique is ideal for imaging these surfaces as a large area of the surface can be imaged with a high vertical resolution (≈2nm). The analysis area was 124.4 x 94.6µm. Data analysis was performed with Wyko Vision 32 (Veeco Instruments, USA) which allows the application of a Gaussian filter to separate waviness and form from roughness.

## Results



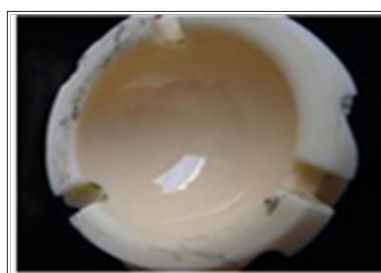
**Figure 1:** Clinical case 1: Macroscopic wear of the retrieved CoC THR first generation retrieved liner.



**Figure 2:** Clinical case 1: Macroscopic wear of the retrieved CoC THR first generation retrieved femoral head.

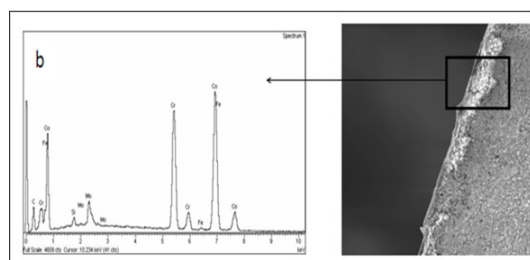


**Figure 3:** Clinical case 2: Macroscopic wear of the retrieved CoC THR first generation retrieved femoral head.



**Figure 4:** Clinical case 2: Macroscopic wear of the retrieved CoC THR first generation retrieved liner.

The femoral heads showed stripe wear and varying degrees of roughened or darkened areas (Figures 1-4). Surface topography of the femoral heads and acetabular cups showed that the unworn areas had a very smooth surface, but the roughened and areas with stripe wear had more peaks and troughs. The calculated lineal wear of the first clinical case head was 41.4µm/year. On the second clinical case, the estimated lineal wear was 48.3µm/year for the head and 18.5µm/year for the socket. Microscopic wear was assessed by quantifying the surface roughness of liners and femoral heads. The average surface roughness was of 549.76±91.25 nm for the head of the first clinical case and 449.96±141.72 nm for the head of the second one in the worn areas. The average surface roughness in the unworn areas was 93.35±70.90 nm for the first clinical case and 79.89±88.97 for the second one. The SEM examination showed abrasive wear. The maximum deviation of the sphericity observed was 3.7% in the head and 2.9% in the socket on the clinical case 1.



**Figure 5:** The black lines on the surface of the ceramic have been analysed by X-Ray microanalysis of the black lines situated on the ceramic surface; they are produced by the wear in Morse-cone with the wear metal-metal, the particles migrate to the ceramic-ceramic surfaces and the metallic debris are embedded on the ceramic surface.

For the clinical case 2, the bigger sphericity deviation was 4.7% in the head and 1.8% in the socket, cracking of the surface with wear marks and alumina particles dislodging of small holes. The black lines on the surface of the ceramic have been analysed by X-Ray microanalysis. The results showed the presence of CoCrMo (MIRAR SI LOS VASTAGOS SON DE Ti6Al4V), these debris are produced by the wear in morse-cone with the wear metal-metal, the particles migrate to the ceramic-ceramic surfaces and the metallic debris are embedded on the ceramic surface, as can be observed in (Figure 5).

## Discussion

Ceramic-on-ceramic bearings have shown to produce the smallest amount of wear volume in in vitro and in vivo studies [6]. However, concerns over ceramic wear, ceramic fracture and catastrophic failures persist and are report in the literature [20-26]. Fewer cases of osteolysis have been reported [8,9,27,28] and fractures rates of modern alumina ceramic bearings published are as low as 1 in 25.000 [9,10,29]. The accepted hypothesis as a causative factor for implant failure is the cyclic impingement between the neck of the stem and the socket. Malposition on the axial plane and misalignment of the ceramic liner during insertion into the cup could be the cause of failure in many instances [30-33]. The femoral heads retrieved in our study showed evidence of stripe wear and the liners showed rim wear, suggesting that edge loading may have been a mechanism of stripe wear. There are few published studies on CoC first generation retrieved implants analysis and all of them have being implant for less than 20 years. Nevelos et al. [12] removed the failed implants after 9 years of follow-up finding stripe or severe wear as Prudhommeaux et al. [13] found on their analysed retrieved implants after 11 years of follow-up. Korim et al [15] retrieval implant analysed was due on implants with less than 16 years of follow-up. Stripe wear was also find in second-generation CoC THR implants retrieved after a mean of 13 years [14].

In previous retrieval analyses, the linear wear has ranged from 42 to 1.821  $\mu\text{m}$  on the femoral side and from 20 to 559  $\mu\text{m}$  on the acetabular side [12, 13]. Compared to other published studies were the head lineal wear has ranged from 42 to 1.821  $\mu\text{m}/\text{year}$ , our result (41.4 and 48.3 $\mu\text{m}/\text{year}$ ) was one of the highest but the implants were retrieved more than 10 years later [12,13]. On the other hand, the liner wear of our study (18.5  $\mu\text{m}/\text{year}$ ) was lower than the ones published in other studies (from 20 to 559  $\mu\text{m}$  per year) [12, 13]. CoC THR in vivo wear rates are bigger than the rates obtained with standard simulator studies [16-19]. Affatato et al. [14] suggested that the wear in alumina-alumina bearings in association with a loose acetabular component may be variable in pattern, and may partially explain why the wear of a ceramic head in vivo may be greater than that seen after in vitro testing of well-functioning joints. At the SEM examination in our study, we have seen alumina wear particles and metal debris incorporated into the ceramic. Although the values of wear measured through the synovial fluid microanalysis were 10 times higher than the ones reported by Mittelmeier and Heisel [2] and Nich et al. [34] there was not perceive any adverse reaction of surrounding tissues to

ceramic particles in our study. The wear rate of ceramic-on-ceramic THA bearings of the first generation (more than 30 years in service) is low enough to allow a high implant survivorship.

## Conclusion

The wear rate of ceramic-on-ceramic THA bearings, even those of the first generation is low enough over time to allow a prolonged durability of implants and a long-term survival of arthroplasty, as it is evident in the two cases studied with more than 30 years in service.

## References


1. Boutin P, Christel P, Dorlot JM, Meunier A, de Roquancourt A, et al. (1988) The use of dense alumina-alumina ceramic combination in total hip replacement. *J Biomed Mater Res* 22(12): 1203-1232.
2. Mittelmeier H, Heisel J (1992) Sixteen-years' experience with ceramic hip prostheses. *Clin Orthop* 282: 64-72.
3. Finkbone PR, Severson EP, Cabanela ME, Trousdale RT (2012) Ceramic-on-ceramic total hip arthroplasty in patients younger than 20 years. *Journal of Arthroplasty* 27(2): 213-219.
4. Kamath AF, Sheth NP, Hosalkar HH, Babatunde OM, Lee GC, et al. (2012) Modern total hip arthroplasty in patients younger than 21 years. *Journal of Arthroplasty* 27(3): 402-408.
5. Faldini C, Miscione MT, Chehrassan M, Aciri F, Pungetti C, et al. (2011) Congenital hip dysplasia treated by total hip arthroplasty using cementless tapered stem in patients younger than 50 years old: results after 12-years follow-up. *Journal of Orthopaedics and Traumatology* 12(4): 213-218.
6. Barrack RL, Burak C, Skinner HB (2004) Concerns about ceramics in THA. *Clin Orthop Relat Res* (429): 73-79.
7. Savarino L, Baldini N, Ciapetti G, Pellacani A, Giunti A (2009) Is wear debris responsible for failure in alumina-on-alumina implants? *Acta Orthop* 80(2): 162-167.
8. Sedel L (2000) Evolution of Alumina-on-Alumina Implants. *Clin Orthop* 379: 48-54.
9. Tateiwa T, Clarke IC, Williams PA, Garino J, Manaka M, et al. (2008) Ceramic total hip arthroplasty in the United States: safety and risk issues revisited. *Am J Orthop (Belle Mead NJ)* 37(2): 26-31.
10. Jeffers J RT, Walter WL (2012) Ceramic-on-ceramic bearings in hip arthroplasty: state of the art and the future. *J Bone Joint Surg (Br)* 94(6): 735-745.
11. Bal BS, Garino J, Ries M, Rahaman MN (2007) A review of ceramic bearing materials in total joint arthroplasty. *HIPInternational* 17(1): 21-30.
12. Nevelos JE, Ingham E, Doyle C, Fisher J, Nevelos AB (1999) Analysis of retrieved alumina ceramic components from Mittelmeier total hip prostheses. *Biomaterials* 20(19): 1833-1840.
13. Prudhommeaux F, Hamadouche M, Nevelos J, Doyle C, Meunier A, et al. (2000) Wear of alumina-on-alumina total hip arthroplasties at a mean 11-year followup. *Clin Orthop* 379: 113-122.
14. Affatato S, Traina F, De Fine M, Carmignato S, Toni A (2012) Alumina-on-alumina hip implants: A wear study of retrieved components. *J Bone Joint Surg (Br)* 94(1): 37-42.
15. Korim M, Scholes S, Unsworth A, Power R (2014) Retrieval analysis of alumina ceramic-on-ceramic bearing couples. *Acta Orthop* 85(2): 133-140.
16. Nevelos JE, Prudhommeaux F, Hamadouche M, Doyle C, Ingham E, et al. (2001) Comparative analysis of two different types of alumina-alumina hip prosthesis retrieved for aseptic loosening. *J Bone Joint Surg (Br)* 83(4): 598-603.

17. Rieker C, Konrad R, Schön R (2001) In vitro comparison of the two hard-hard articulations for total hip replacements. *Proc Inst Mech Eng H* 215(2): 153-160.
18. Tipper JL, Hatton A, Nevelos JE, Ingham E, Doyle C, Streicher R, et al. (2002) Alumina-alumina artificial hip joints. Part II: characterisation of the wear debris from in vitro hip joint simulations. *Biomaterials* 23(16): 3441-3448.
19. Stewart TD, Tipper JL, Insley G, Streicher RM, Ingham E, et al. (2003) Long-term wear of ceramic matrix composite materials for hip prostheses under severe swing phase microseparation. *J Biomed Mater Res B Appl Biomater* 66(2): 567-573.
20. Anwar I, Bhatnagar G, Atrah S (2009) Delayed catastrophic failure of a ceramic head in hybrid total hip arthroplasty. *J Arthroplasty* 24(1): 158.e5-8.
21. Mc Carthy MJ, Halawa M (2007) Lining up the liner: 2 case reports of early ceramic liner fragmentation. *J Arthroplasty* 22(8): 1217-1222.
22. Toran MM, Cuenca J, Martinez AA, Herrera A, Thomas JV (2006) Fracture of a ceramic femoral head after ceramic-on-ceramic total hip arthroplasty. *J Arthroplasty* 21(7): 1072-1073.
23. Hasegawa M, Sudo A, Hirata H, Uchida A (2003) Ceramic acetabular liner fracture in total hip arthroplasty with a ceramic sandwich cup. *J Arthroplasty* 18(5): 658-661.
24. Lee SC, Jung KA, Nam CH, Kim TH, Ahn NK, Hwang SH (2010) Acetabular screw head-induced ceramic acetabular liner fracture in cementless ceramic-on-ceramic total hip arthroplasty. *Orthopedics* 33(5).
25. Michaud RJ, Rashad SY (1995) Spontaneous fracture of the ceramic ball in a ceramic-polyethylene total hip arthroplasty. *J Arthroplasty* 10(6): 863-867.
26. Pulliam IT, Trousdale RT (1997) Fracture of a ceramic femoral head after a revision operation. A case report. *J Bone Joint Surg Am* 79(1): 118-121.
27. Yoon TR, Rowe SM, Jung ST, Seon KJ, Maloney WJ (1998) Osteolysis in association with a total hip arthroplasty with ceramic bearing surfaces. *J Bone Joint Surg (Am)* 80(10):1459-1468.
28. Hannouche D, Zaoui A, Zadegan F, Sedel L, Nizard R (2011) Thirty years of experience with alumina-on-alumina bearings in total hip arthroplasty. *Int Orthop* 35(2):207-213.
29. Nizard R, Sedel L, Hannouche D, Hamadouche M, Bizot P (2005) Alumina pairing in total hip replacement. *J Bone Joint Surg (Br)* 87(6): 755-758.
30. Min BW, Song KS, Kang CH, Bae KC, Won YY, et al. (2007) Delayed fracture of a ceramic insert with modern ceramic total hip replacement. *J Arthroplasty* 22(1):136-139.
31. Hamilton WG, McAuley JP, Dennis DA, Murphy JA, Blumenfeld TJ, et al. (2010) THA with delta ceramic on ceramic: results of a multicenter investigational device exemption trial. *Clinical Orthopaedics and Related Research* 468(2): 358-366.
32. Traina F, De Fine M, Bordini B, Toni A (2012) Risk factors for ceramic liner fractures after total hip arthroplasty. *Hip International* 22(6): 607-614.
33. McAuley JP, Dennis DA, Grostefon J, Hamilton WG (2012) Factors affecting modular acetabular ceramic liner insertion: a biomechanical analysis. *Clinical Orthopaedics and Related Research* 470(2): 402-409.
34. Nich C, Sariali el-H, Hannouche D, Nizard R, Witvoet J, et al. (2003) Long-term results of alumina-on-alumina hip arthroplasty for osteonecrosis. *Clin Orthop Relat Res* 417: 102-111.



This work is licensed under Creative Commons Attribution 4.0 License

Submission Link: <http://biomedres.us/submit-manuscript.php>



#### Assets of Publishing with us

- Global archiving of articles
- Immediate, unrestricted online access
- Rigorous Peer Review Process
- Authors Retain Copyrights
- Unique DOI for all articles

<http://biomedres.us/>